

50 EXTRACTING FORCEPS



 **Wrangler**
Instruments

www.wrangler.pk

Zahnzangen, Englische Form
Extracting Forceps, English Pattern
Pinze per estrazione, Forma Inglese
Pinzas da extracción, Forma Inglesa
Daviers, Forme Anglaise

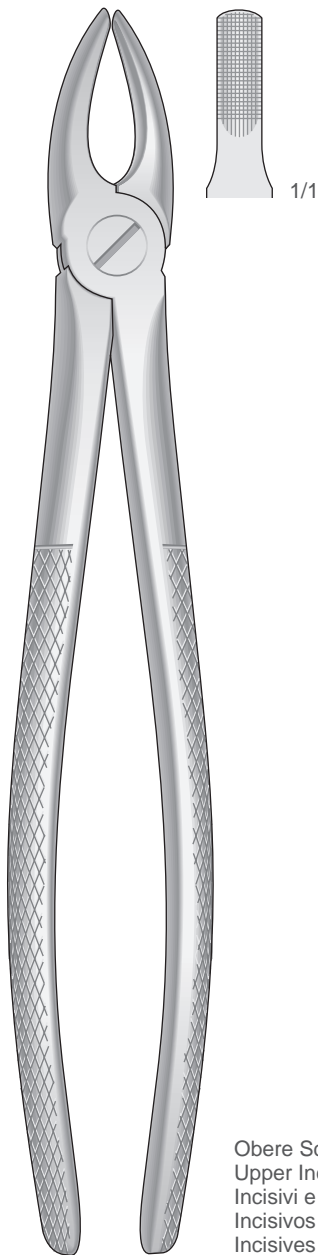


Fig. 1
50-100-01

Obere Schneide- und Eckzähne
Upper Incisors and cuspids
Incisivi e canini superiori
Incisivos y caninos superiores
Incisives et canines supérieures

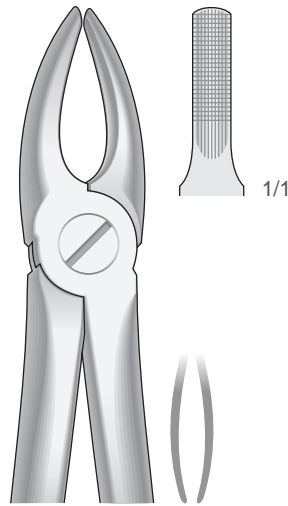


Fig. 2
50-100-02

Obere Schneide- und Eckzähne
Upper Incisors and cuspids
Incisivi e canini superiori
Incisivos y caninos superiores
Incisives et canines supérieures

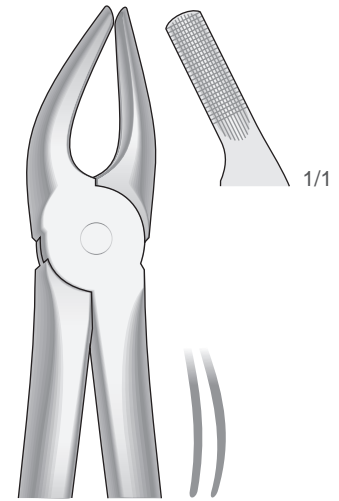


Fig. 7
50-100-07

Obere Prämolaren
Upper premolars
Premolari superiori
Premolares superiores
Prémolaires supérieures

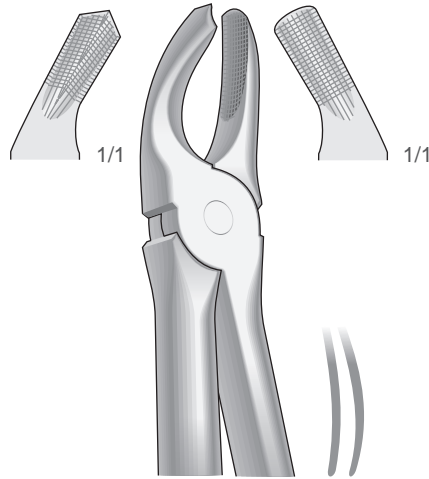


Fig. 17
50-100-17

Obere Molaren, rechts
Upper molars, right
Molari superiori, destra
Molares superiores, derechos
Molaires supérieures, droites

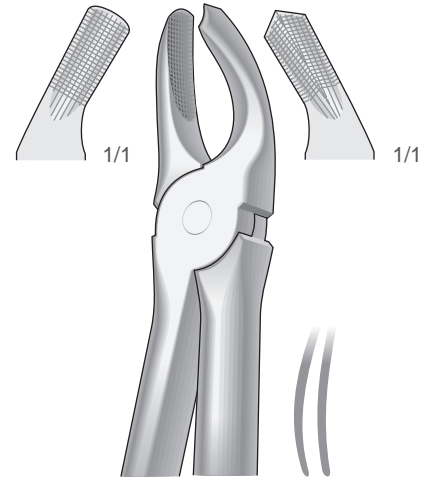
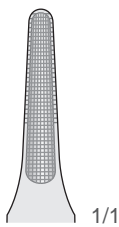



Fig. 18
50-100-18

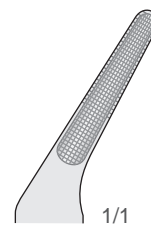
Obere Molaren, links
Upper molars, left
Molari superiori, sinistra
Molares superiores, izquierdos
Molaires supérieures, gauches

Zahnzangen, Englische Form
Extracting Forceps, English Pattern
Pinze per estrazione, Forma Inglese
Pinzas da extracción, Forma Inglesa
Daviers, Forme Anglaise



Obere Wurzeln und Schneidezähne
Upper Roots and incisors
Radici e incisivi superiori
Raíces y incisivos superiores
Racines et incisives supérieures

Fig. 29
50-100-29



Obere Wurzeln
Upper Roots
Radici superiori
Raíces superiores
Racines supérieures

Fig. 30
50-100-30

Zahnzangen, Englische Form
Extracting Forceps, English Pattern
Pinze per estrazione, Forma Inglese
Pinzas da extracción, Forma Inglesa
Daviers, Forme Anglaise

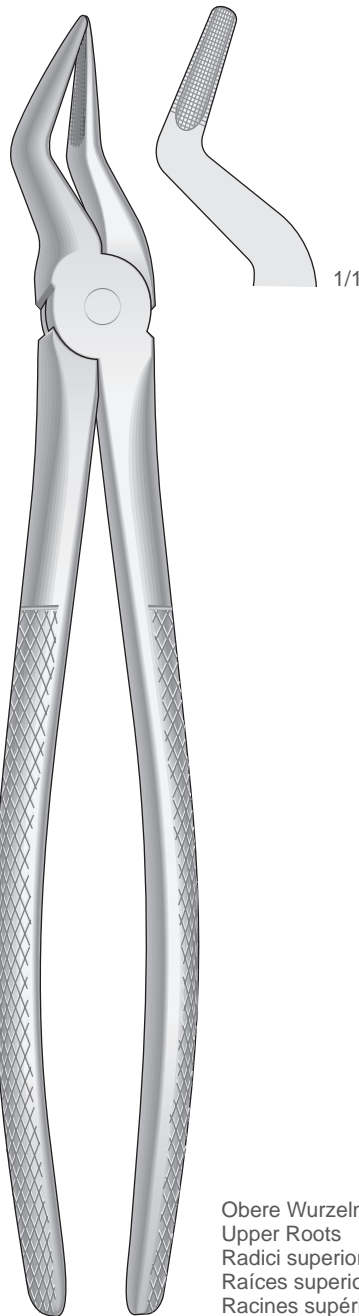


Fig. 51
50-110-51

Obere Wurzeln
Upper Roots
Radici superiori
Raíces superiores
Racines supérieures

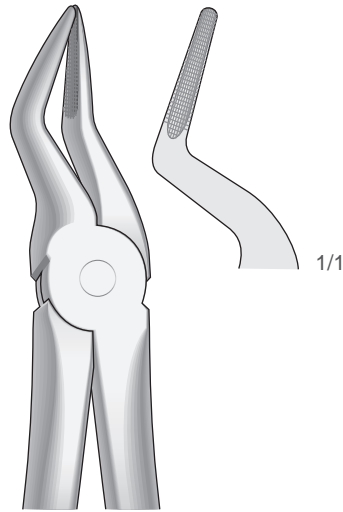


Fig. 51A
50-110-51A

Obere Wurzeln
Upper Roots Radici
superiori Raíces
superiores Racines
supérieures

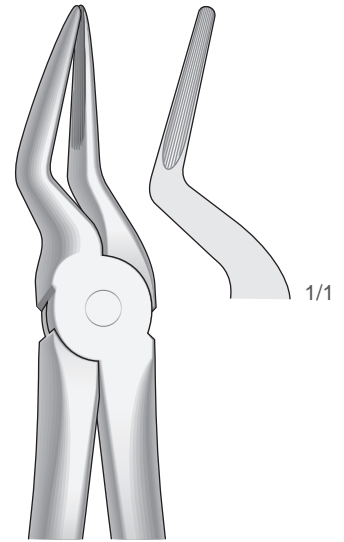


Fig. 51AL
50-110-51L

Obere Wurzeln
Upper Roots Radici
superiori Raíces
superiores Racines
supérieures

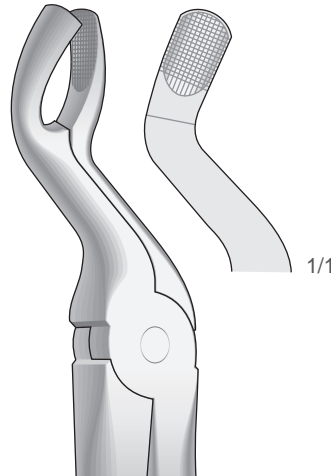


Fig. 67A
50-110-67A

Obere Dritte Molaren - Für Obere Weisheitszähne
Upper molars - For Upper wisdom teeth
Ottavi superiori - Per denti del giudizio superiori
Molares superiores - Para muelas del juicio superiores
Molaires supérieures - Pour dents de sagesse supérieures

Zahnzangen, Englische Form
Extracting Forceps, English Pattern
Pinze per estrazione, Forma Inglese
Pinzas da extracción, Forma Inglesa
Daviers, Forme Anglaise

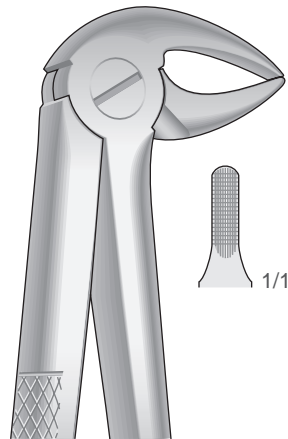


Fig. 33
50-120-33

Untere Prämolaren, Schneidezähne und Wurzeln
Lower incisors, premolars and roots
Incisivi, premolari e radici inferiori
Incisivos, premolares y raíces inferiores
Incisives, prémolaires et racines inférieures

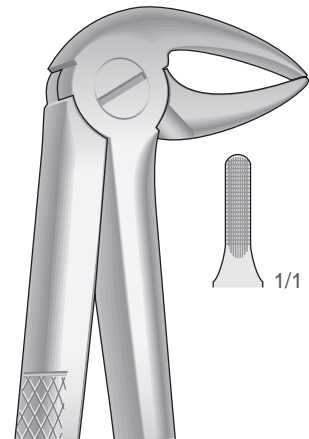


Fig. 33A
50-120-33A

Untere Wurzeln, schlankes Maul
Lower roots, Slender jaw
Radici inferiori, morso stretto
Raíces inferiores, boca estrecha
Racines inférieures, avec un bec très fin




Fig. 13
50-120-13

Untere Eckzähne und Prämolaren
Lower cuspids and premolars
Canini e premolari inferiori
Caninos y premolares inferiores
Canines et prémolaires inférieures

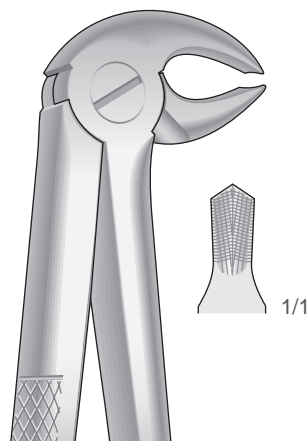


Fig. 22
50-120-22

Untere Molaren
Lower molars
Molari inferiori
Molares inferiores
Molaires inférieures

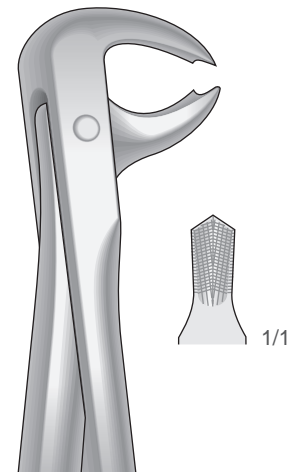


Fig. 73
50-120-73

Untere Molaren
Lower molars
Molari inferiori
Molares inferiores
Molaires inférieures

Zahnzangen, Englische Form
Extracting Forceps, English Pattern
Pinze per estrazione, Forma Inglese
Pinzas da extracción, Forma Inglesa
Daviers, Forme Anglaise

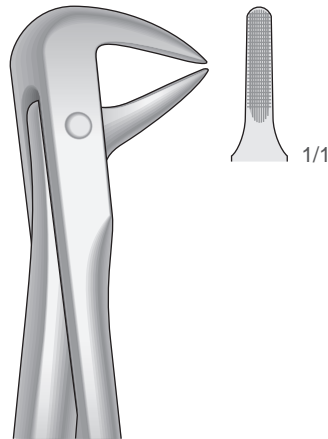


Fig. 74N
50-130-74N

Untere Wurzeln, schneide-und Eckzähne
Lower roots, Incisors and bicuspid
Radici, incisivi e canini inferiori
Raíces, incisivos y caninos inferiores
Racines, incisives et canines inférieures

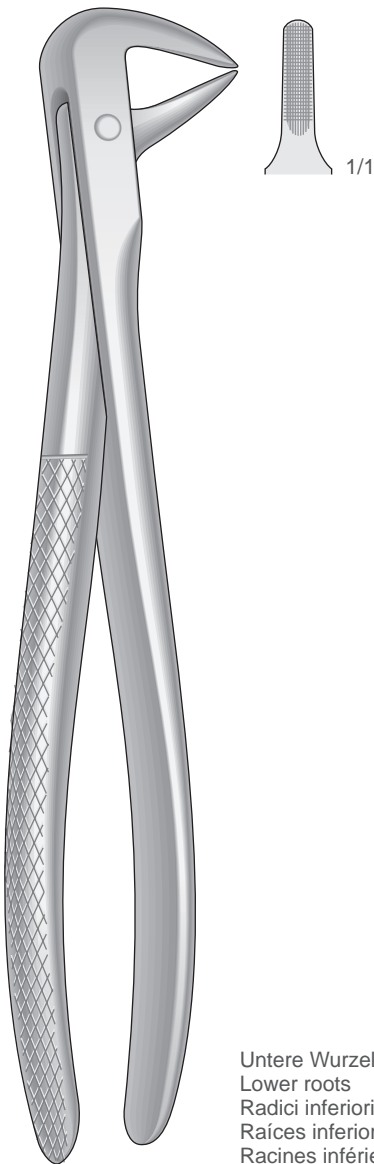


Fig. 74
50-130-74

Untere Wurzeln
Lower roots
Radici inferiori
Raíces inferiores
Racines inférieures

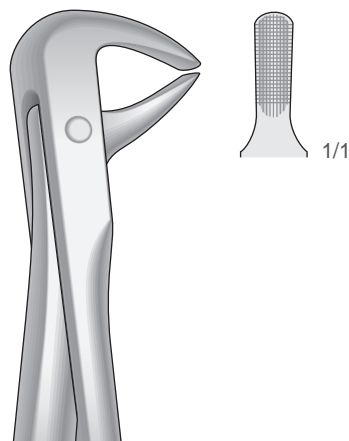


Fig. 75
50-130-75

Untere Eckzähne und Prämolaren
Lower Cuspids and bicuspid
Canini e premolari inferiori
Caninos y premolares inferiores
Canines et prémolaires inférieures

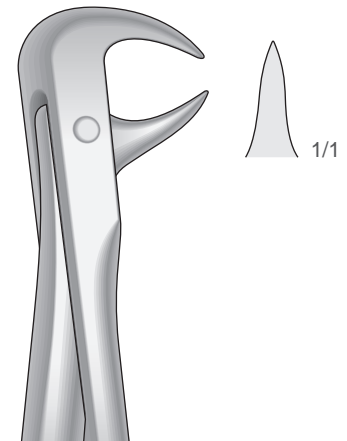


Fig. 86A
50-130-86A

Untere Molaren
Lower molars
Molari inferiori
Molares inferiores
Molaires inférieures

Zahnzangen, Englische Form
Extracting Forceps, English Pattern
Pinze per estrazione, Forma Inglese
Pinzas da extracción, Forma Inglesa
Daviers, Forme Anglaise

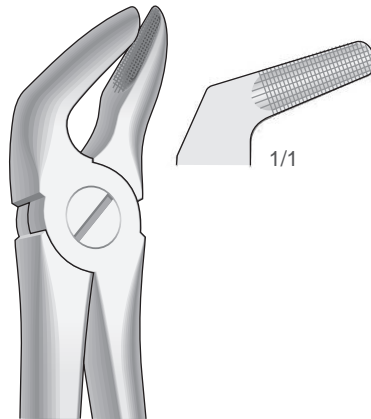


Fig. 8
50-140-8

Untere Prämolaren
Lower premolars
Premolari inferiori
Premolares inferiores
Prémolaires inférieures

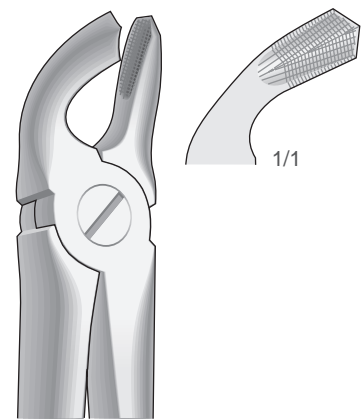


Fig. 21
50-140-21

Untere Weisheitszähne und Molaren
Lower wisdom teeth and molars
Denti del giudizio e molari inferiori
Muelas del juicio y Molares inferiores
Dents de sagesse et molaires inférieures




Fig. 4
50-140-4

Untere Schneide- und Eckzähne
Lower Incisors and cuspids
Incisivi e canini inferiori
Incisivos y caninos inferiores
Incisives et canines inférieures

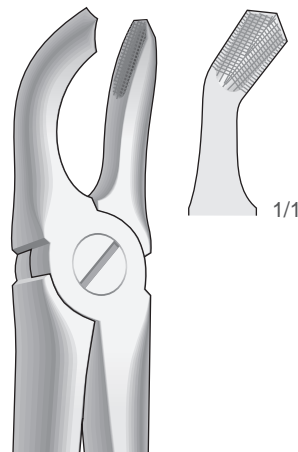
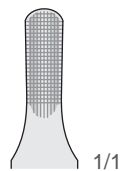


Fig. 79
50-140-79

Untere Weisheitszähne
Lower wisdom teeth
Denti del giudizio inferiori
Muelas del juicio inferiores
Dent de sagesse inférieures

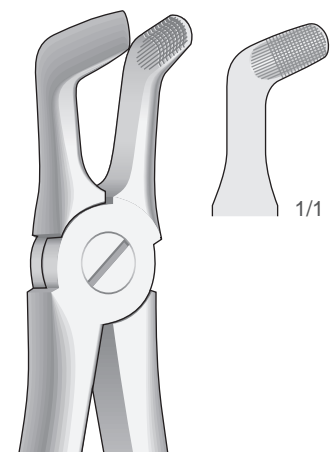


Fig. 79A
50-140-79A

Untere Molaren und Weisheitszähne
Lower molars and wisdom teeth
Molari e denti del giudizio inferiori
Molares y muelas del juicio inferiores
Molaires et dent de sagesse inférieures

Zahnzangen, Englische Form
Extracting Forceps, English Pattern
Pinze per estrazione, Forma Inglese
Pinzas da extracción, Forma Inglesa
Daviers, Forme Anglaise

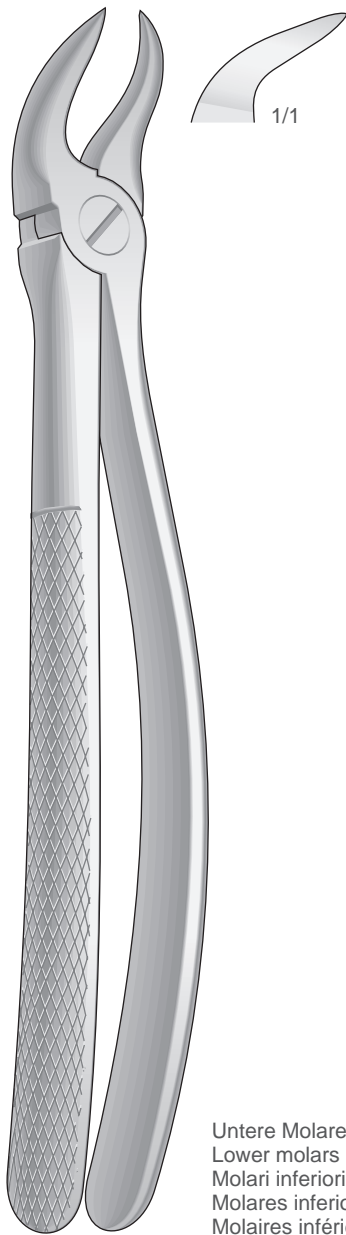


Fig. 87
50-150-87

Untere Molaren
Lower molars
Molari inferiori
Molares inferiores
Molaires inférieures

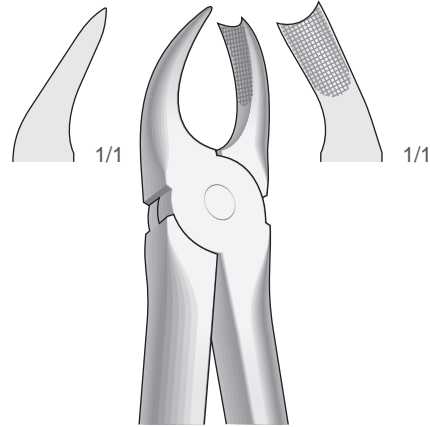


Fig. 89
50-150-89

Obere Molaren, rechts
Upper molars, right
Molari superiori, destra
Molares superiores, derechos
Molaires supérieures, droites

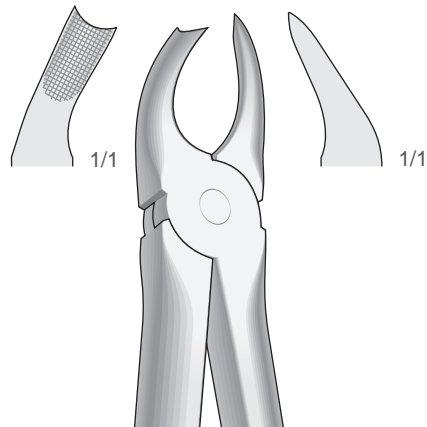


Fig. 90
50-150-90

Obere Molaren, links
Upper molars, left
Molari superiori, sinistra
Molares superiores, izquierdos
Molaires supérieures, gauches

Zahnzangen, Englische Form
 Extracting Forceps, English Pattern
 Pinze per estrazione, Forma Inglese
 Pinzas da extracción, Forma Inglesa
 Daviers, Forme Anglaise

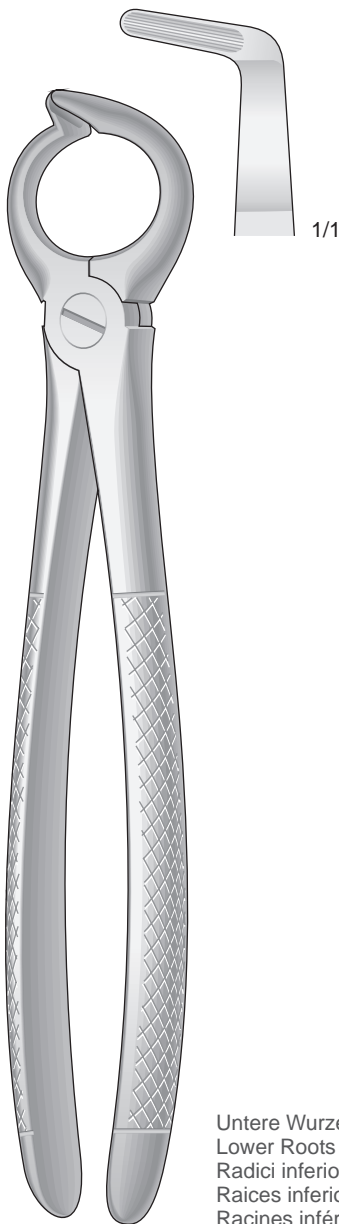


Fig. 68
50-160-68

Untere Wurzeln
 Lower Roots
 Radici inferiori
 Raíces inferiores
 Racines inférieures

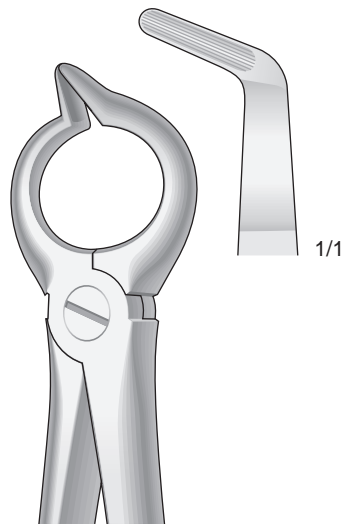


Fig. 68A
50-160-68A

Untere Wurzeln
 Lower Roots
 Radici inferiori
 Raíces inferiores
 Racines inférieures

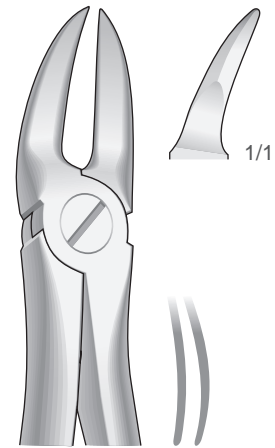


Fig. 55
50-160-55

Zum Trennen oberer Molarenwurzeln
 For separating upper molar roots
 Per radici dei molari superiori, presa in profondità
 Para partir raíces de molares superiores, profundo
 Pour séparer les racines des molaires supérieures

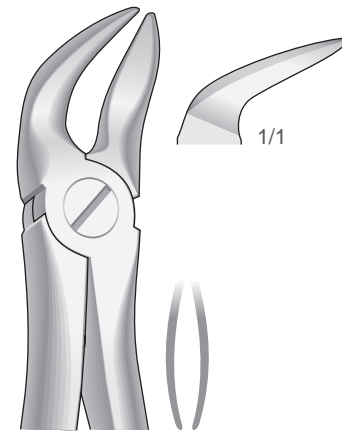
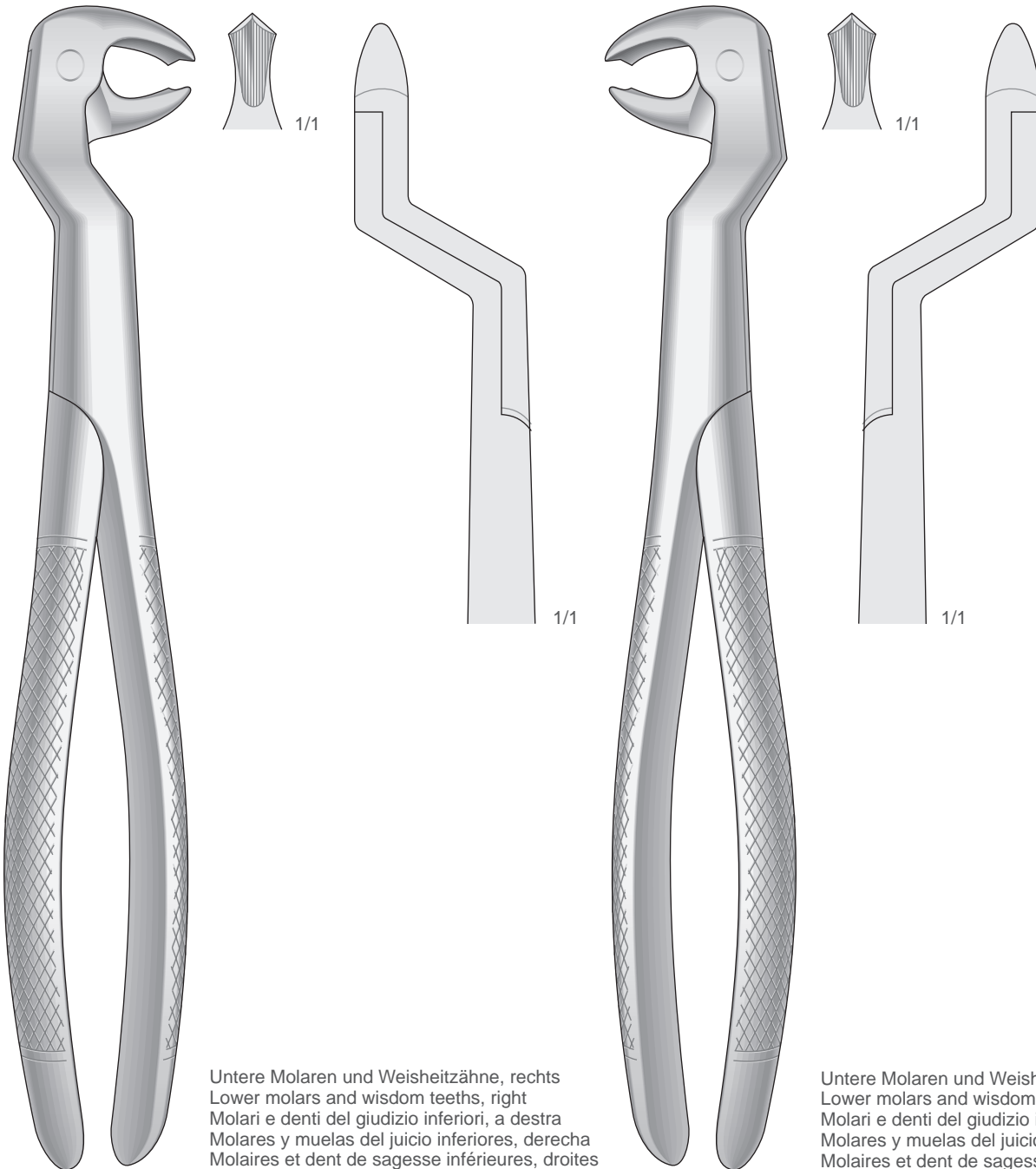


Fig. 56
50-160-56

Zum Trennen Unterer Molarenwurzeln
 For separating lower molar roots
 Per radici dei molari inferiori, presa in profondità
 Para partir raíces de molares inferiores, profundo
 Pour séparer les racines des molaires inférieures

Zahnzangen, Englische Form
Extracting Forceps, English Pattern
Pinze per estrazione, Forma Inglese
Pinzas da extracción, Forma Inglesa
Daviers, Forme Anglaise



Untere Molaren und Weisheitszähne, rechts
Lower molars and wisdom teeth, right
Molari e denti del giudizio inferiori, a destra
Molares y muelas del juicio inferiores, derecha
Molaires et dent de sagesse inférieures, droites

Untere Molaren und Weisheitszähne, links
Lower molars and wisdom teeth, left
Molari e denti del giudizio inferiori, a sinistra
Molares y muelas del juicio inferiores, izquierda
Molaires et dent de sagesse inférieures, gauches

ROUTURIER

50-170-22R

ROUTURIER

50-170-22L

Zahnzangen, Englische Form
Extracting Forceps, English Pattern
Pinze per estrazione, Forma Inglese
Pinzas da extracción, Forma Inglesa
Daviers, Forme Anglaise

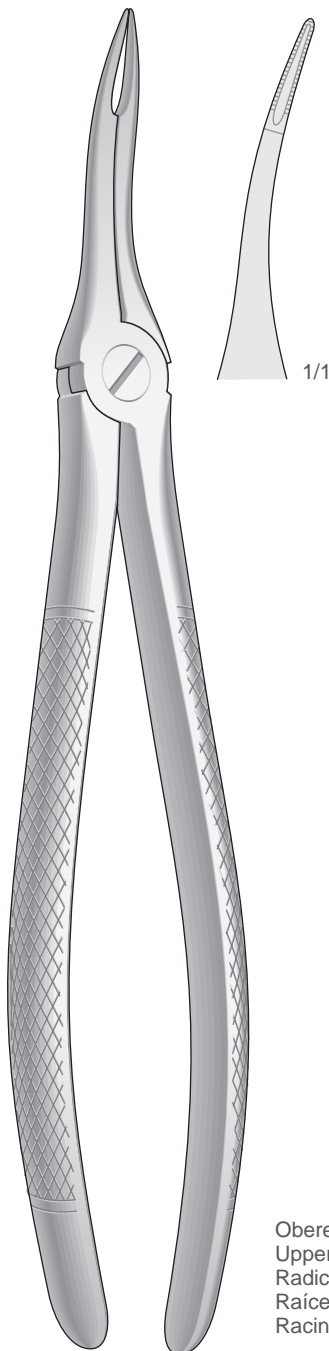


Fig. 49
50-180-49

Obere Wurzeln sehr feine
Upper very fine roots
Radici superiori molto sottili
Raíces superiores muy finas
Racines supérieures très fines

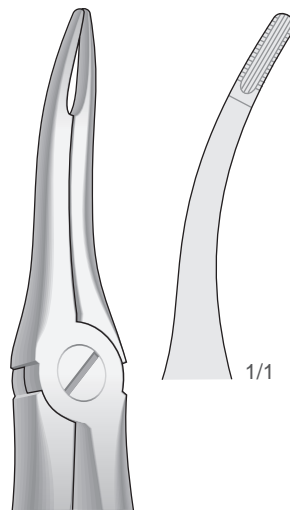


Fig. 48 - 44

Obere Wurzeln
Upper roots
Radici superiori
Raíces superiores
Racines supérieures

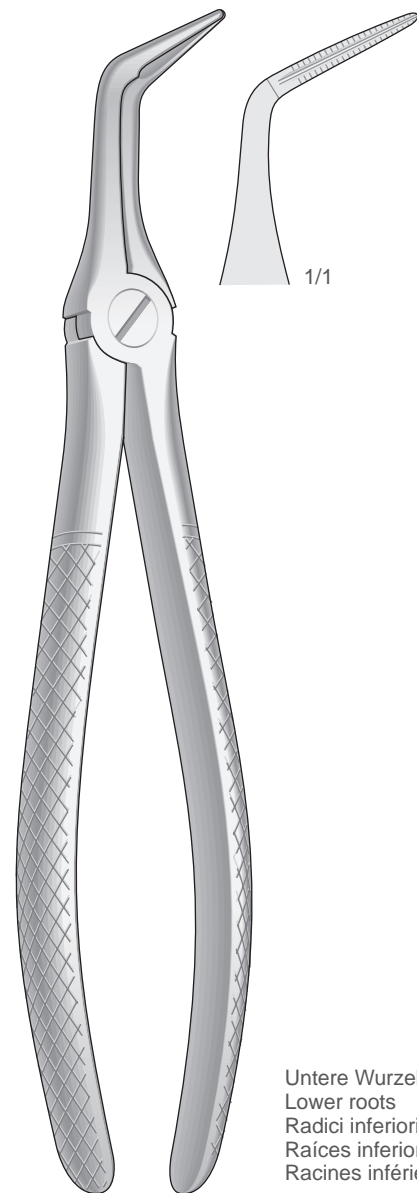


Fig. 46L
50-190-46L

Untere Wurzeln
Lower roots
Radici inferiori
Raíces inferiores
Racines inférieures

Zahnzangen, Paßformgriff
Extracting Forceps, Anatomical Handle
Pinze per estrazione, Manico anatomico
Pinzas da extracción, Mango anatómico
Daviers, Manche anatomique

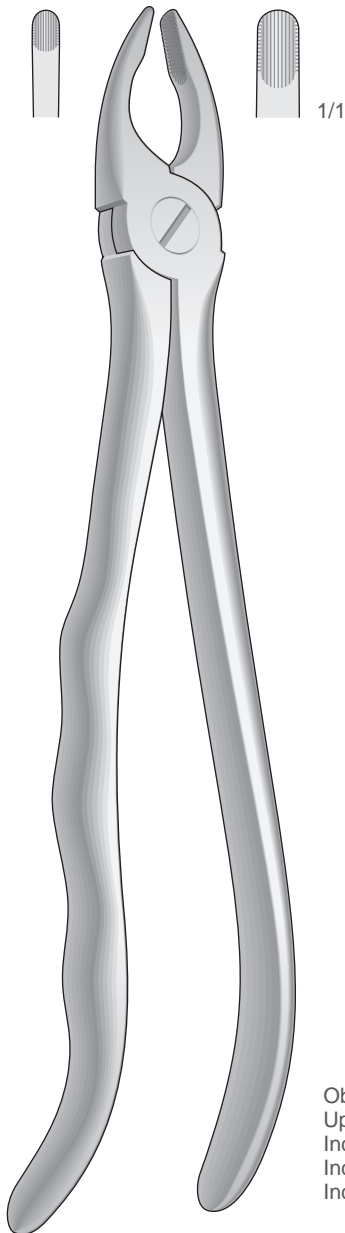


Fig. 3
50-200-3

Obere Schneide- und Eckzähne
Upper incisors and cuspids
Incisivi e canini superiori
Incisivos y caninos superiores
Incisives et canines supérieures

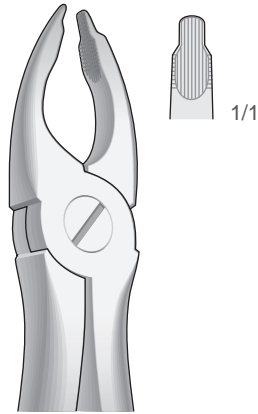


Fig. 34
50-200-34

Obere Schneide- und Eckzähne
Upper incisors and cuspids
Incisivi e canini superiori
Incisivos y caninos superiores
Incisives et canines supérieures

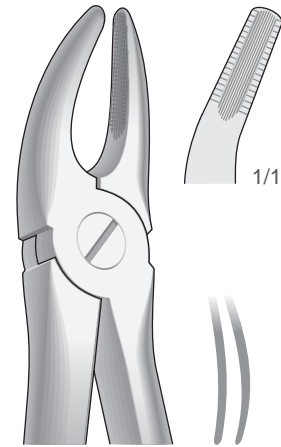


Fig. 7
50-200-7

Obere Prämolaren
Upper premolars
Premolari superiori
Premolares superiores
Prémolaires supérieures

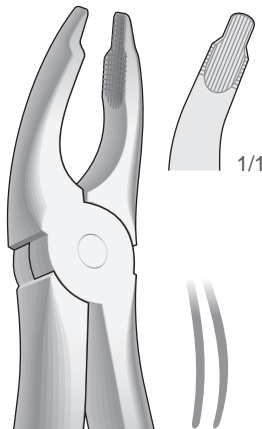


Fig. 35
50-200-35

Obere Schneidezähne und Prämolaren, tiefgreifend
Upper incisors and bicuspid, deep-gripping
Incisivi e premolari superiori, presa in profondità
Incisivos y premolares superiores, a gran calado
Incisives et prémolaires supérieures, à attaque profonde

Zahnzangen, Paßformgriff
Extracting Forceps, Anatomical Handle
Pinze per estrazione, Manico anatomico
Pinzas da extracción, Mango anatómico Daviers, Manche anatomique

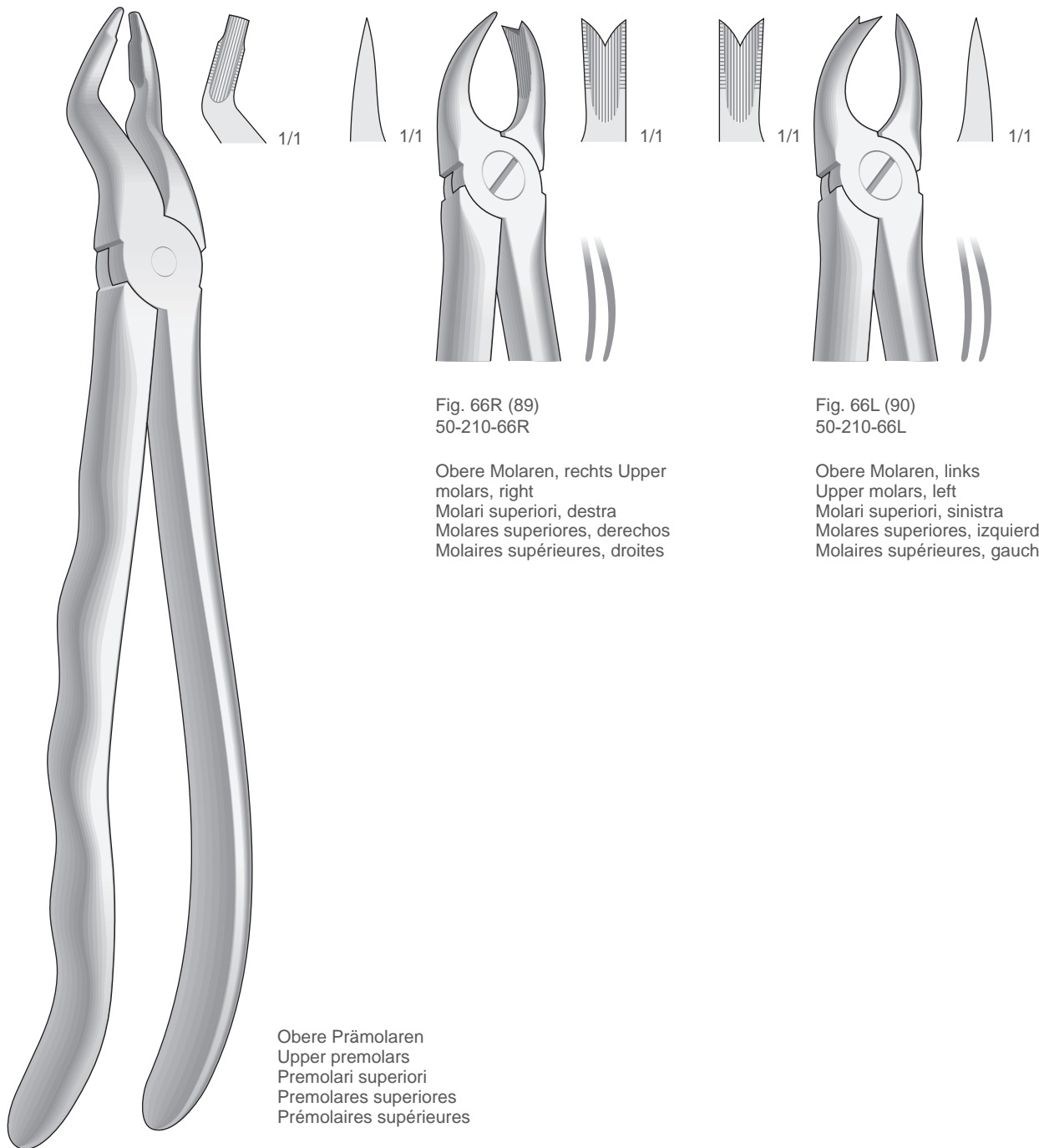


Fig. 31
50-210-31

Obere Prämolaren
Upper premolars
Premolari superiori
Premolares superiores
Prémolaires supérieures

Fig. 66R (89)
50-210-66R

Obere Molaren, rechts
Upper molars, right
Molari superiori, destra
Molares superiores, derechos
Molaires supérieures, droites

Fig. 66L (90)
50-210-66L

Obere Molaren, links
Upper molars, left
Molari superiori, sinistra
Molares superiores, izquierdos
Molaires supérieures, gauches

Zahnzangen, Paßformgriff

Extracting Forceps, Anatomical Handle

Pinze per estrazione, Manico anatomico

Pinzas da extracción, Mango anatómico

Daviers, Manche anatomique

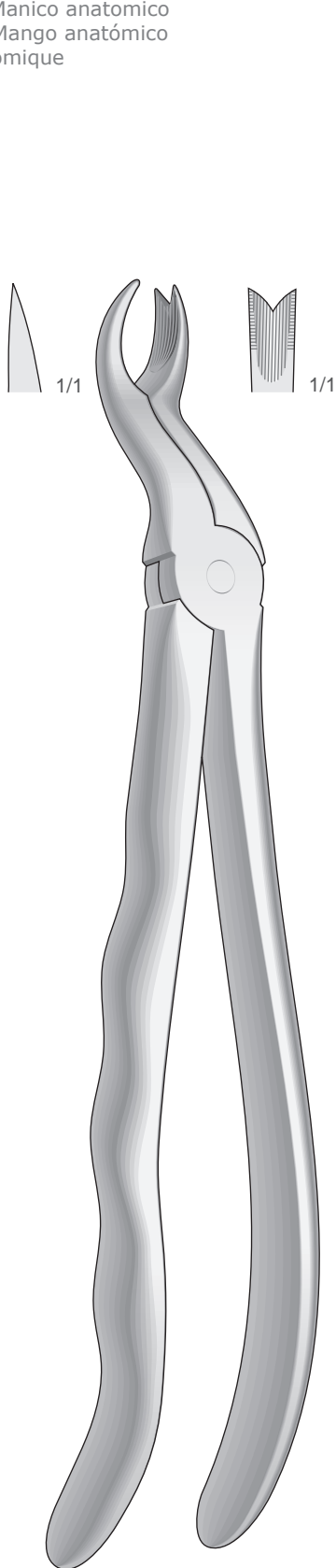


Fig. 67R
50-220-67R

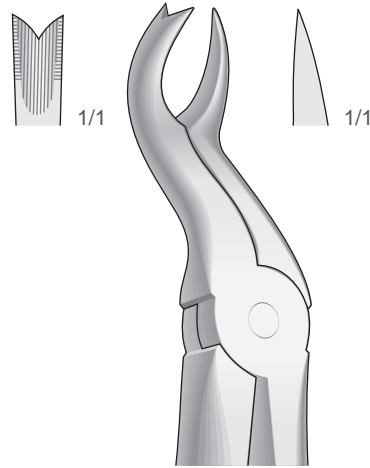


Fig. 67L
50-220-67L

Obere Molaren, links
Upper molars, left
Molari superiori, sinistra
Molares superiores, izquierdos
Molaires supérieures, gauches

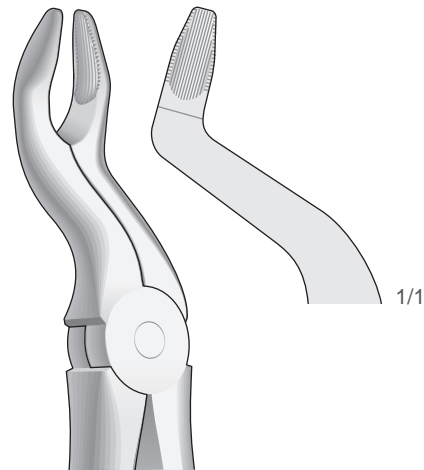
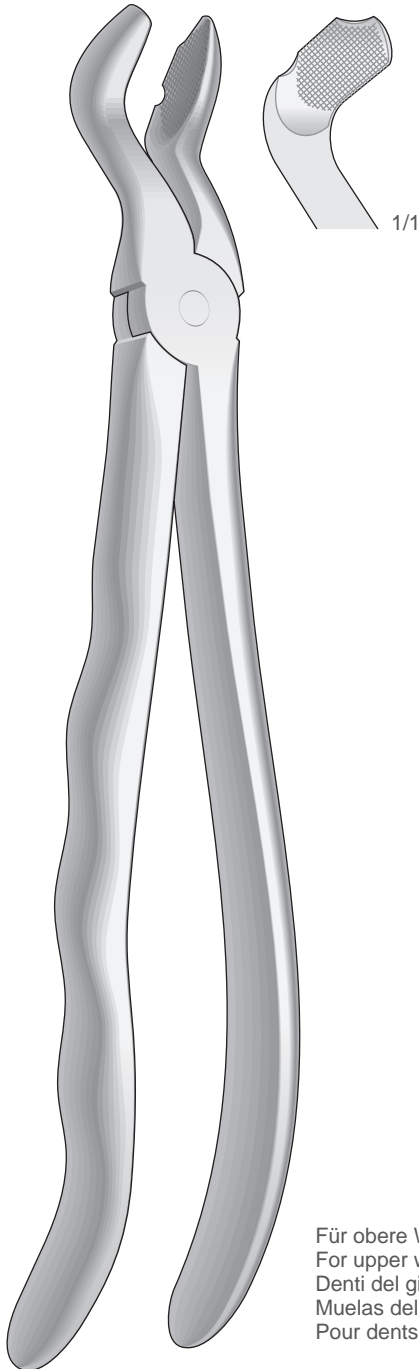


Fig. 67N
50-220-67N

Obere Molaren
Upper molars
Molari superiori
Molares superiores
Molaires supérieures

Obere Molaren, rechts
Upper molars, right
Molari superiori, destra
Molares superiores, derechos
Molaires supérieures, droites

Zahnzangen, Paßformgriff
Extracting Forceps, Anatomical Handle
Pinze per estrazione, Manico anatomico
Pinzas da extracción, Mango anatómico
Daviers, Manche anatomique



FELSCH
Fig. 80
50-230-80

Für obere Weisheitszähne, mit Fangvorrichtung
For upper wisdom teeth, with retaining device
Denti del giudizio superiori, con dispositivo di presa
Muelas del juicio superiores, con dispositivo de retencion
Pour dents de sagesse supérieures, mors conçus pour recueillir la dent

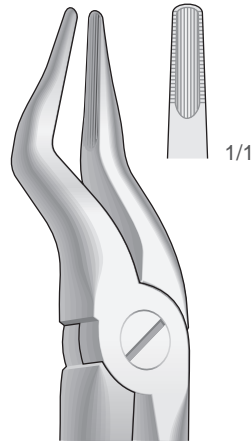


Fig. 51B
50-230-51B

Obere Dritte
Molaren Upper
molars Ottavi
superiori Molares
superiores Molaires
supérieures

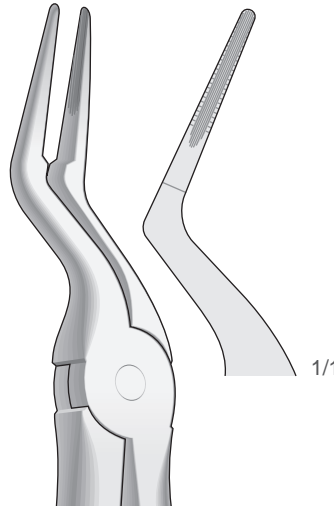


Fig. 97
50-230-97

Obere Wurzelplitterzange
Upper Root Fragments Frammenti
e radici superiori Fragmentos de
raíces superiores Fragments des
racines supérieures

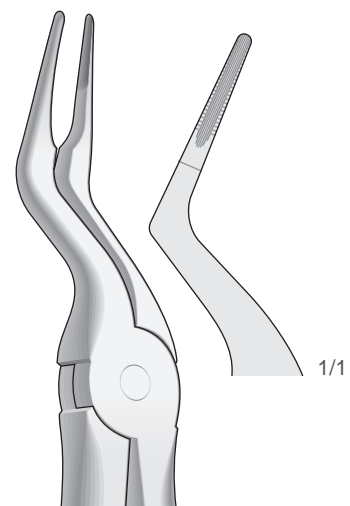


Fig. 97B
50-230-97B

Obere Wurzelplitterzange
Upper Root Fragments Frammenti
e radici superiori Fragmentos de
raíces superiores Fragments des
racines supérieures

Zahnzangen, Paßformgriff
Extracting Forceps, Anatomical Handle
Pinze per estrazione, Manico anatomico
Pinzas da extracción, Mango anatómico
Daviers, Manche anatomique

Obere Wurzeln sehr feine
Upper very fine roots
Radici superiori molto sottili
Raíces superiores muy finas
Racines supérieures très fines

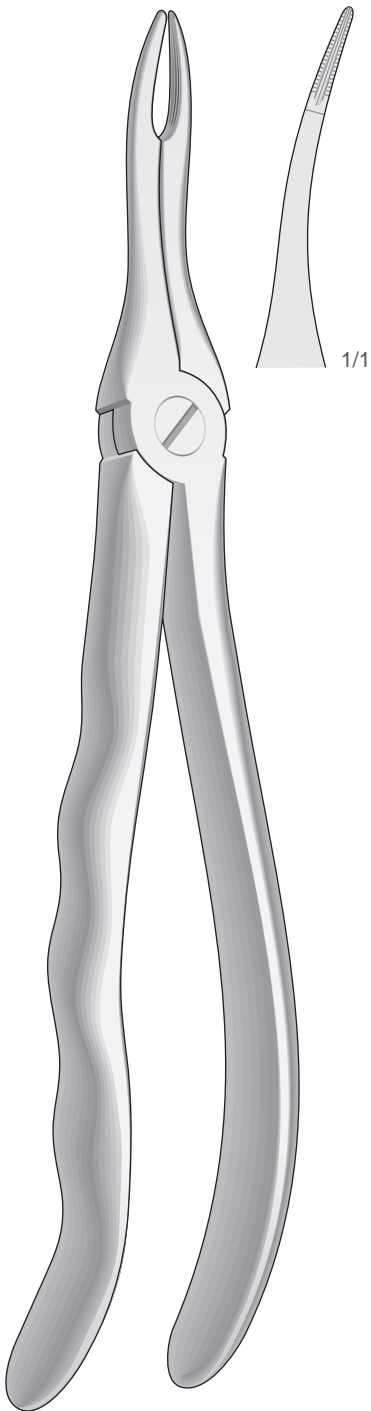


Fig. 49
50-240-49

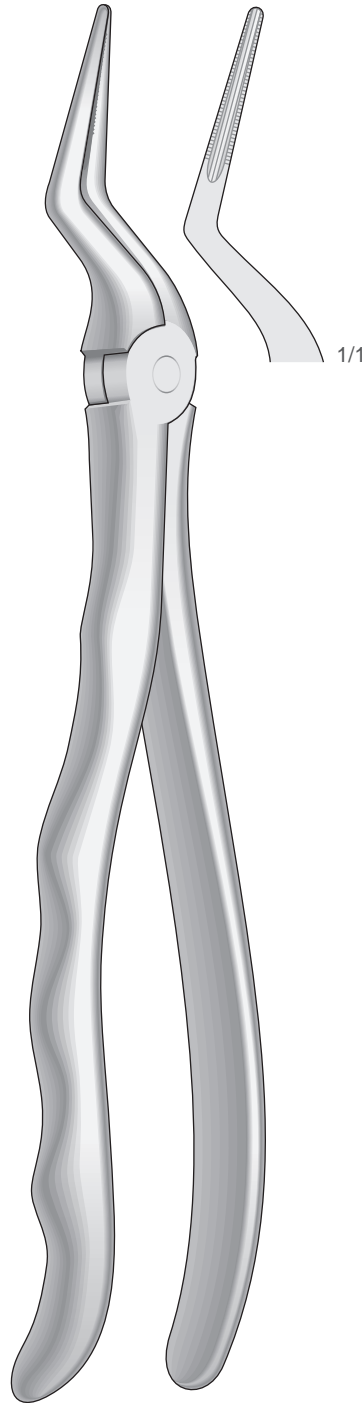


Fig. 51LX
50-240-51LX

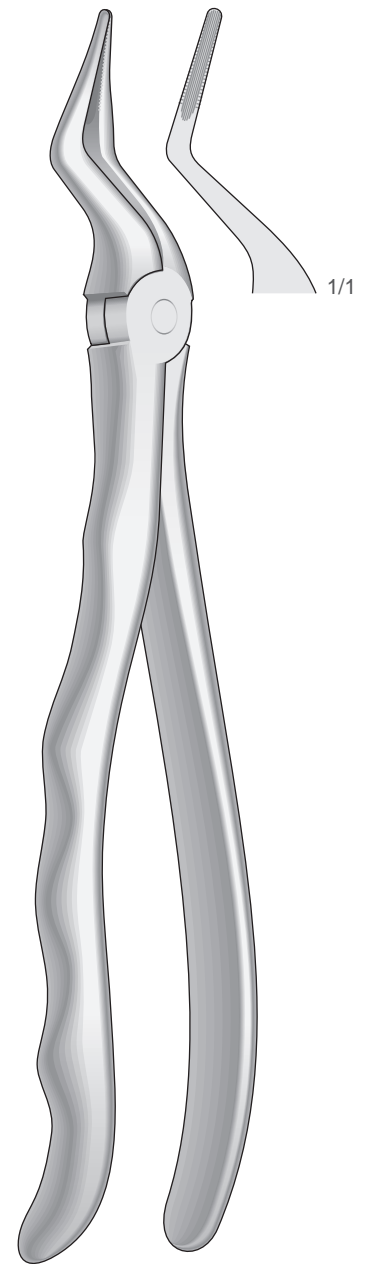


Fig. 351S
50-240-351S

Zahnzangen, Paßformgriff
Extracting Forceps, Anatomical Handle
Pinze per estrazione, Manico anatomico
Pinzas da extracción, Mango anatómico
Daviers, Manche anatomique

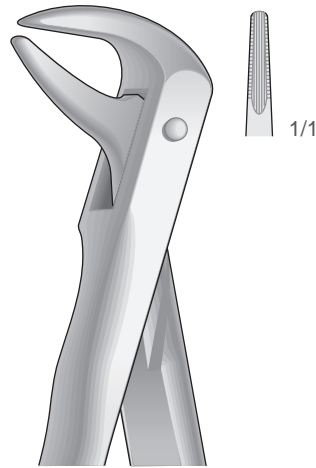


Fig. 74N
50-250-74N

Untere Wurzeln Schneide- und
Eckzähne Lower roots, incisors and
cuspids Radici, incisivi e canini inferiori
Raíces, incisivos y caninos inferiores
Racines, incisives et canines inférieures

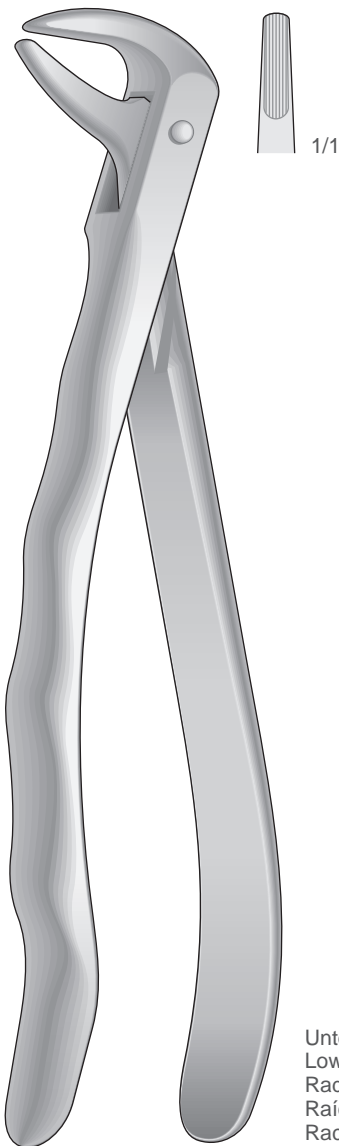


Fig. 74
50-250-74

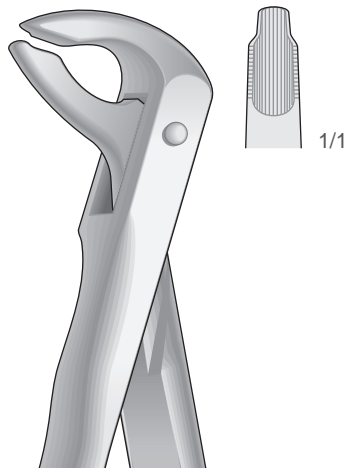


Fig. 36
50-250-36

Untere Wurzeln Schneide- und
Eckzähne Lower roots, incisors and
cuspids Radici, incisivi e canini inferiori
Raíces, incisivos y caninos inferiores
Racines, incisives et canines inférieures

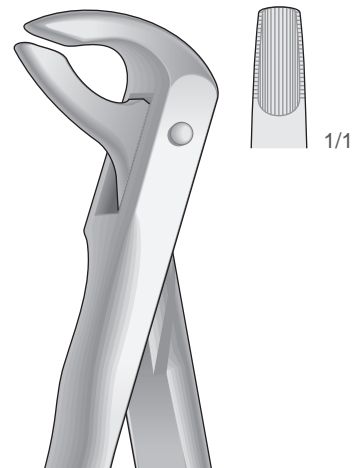


Fig. 36N
50-250-36N

Untere Wurzeln Schneide- und
Eckzähne Lower roots, incisors and
cuspids Radici, incisivi e canini inferiori
Raíces, incisivos y caninos inferiores
Racines, incisives et canines inférieures

Untere Wurzeln Schneide- und Eckzähne
Lower roots, incisors and cuspids
Radici, incisivi e canini inferiori
Raíces, incisivos y caninos inferiores
Racines, incisives et canines inférieures

Zahnzangen, Paßformgriff
Extracting Forceps, Anatomical Handle
Pinze per estrazione, Manico anatomico
Pinzas da extracción, Mango anatómico
Daviers, Manche anatomique

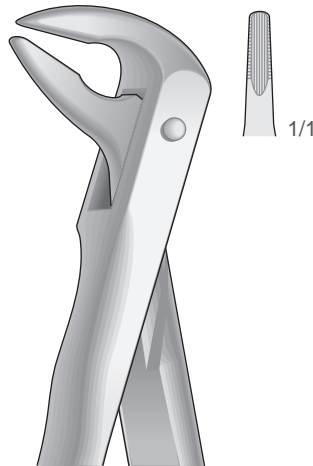


Fig. 59
50-260-59

Untere Wurzelplitterzange
Lower Root Fragments
Frammenti e radici inferiori
Fragmentos de raíces inferiores
Fragments des racines
inférieures

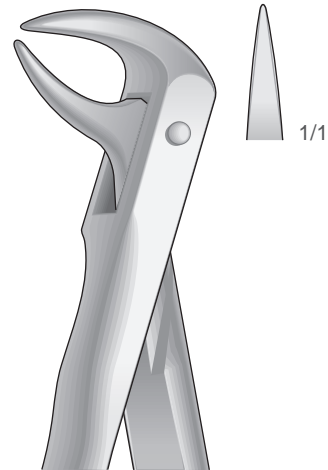


Fig. 86C
50-260-86C

Untere Molaren mit kariesen oder abgebrochenen
Kronen Lower molars with carious or broken caps
Molari inferiori con corone cariate o spezzate
Molares inferiores con coronas rotas o cariadas Molaires
inférieures avec couronnes cariées ou cassées

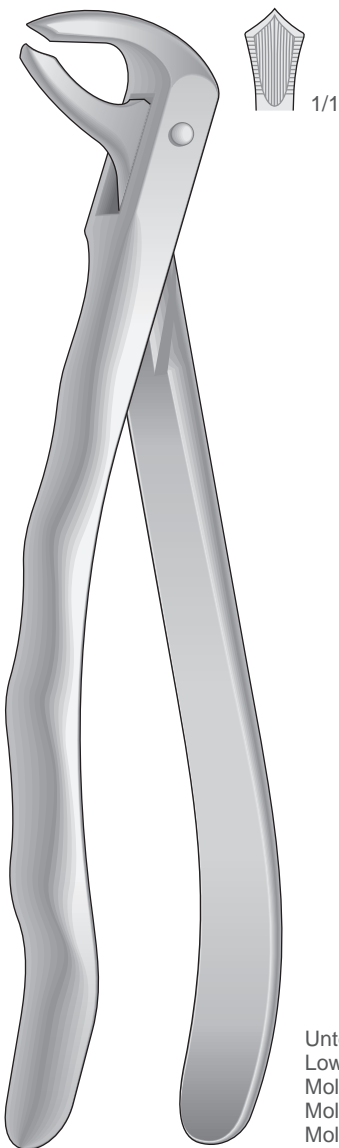


Fig. 73
50-260-73

Untere Molaren
Lower molars
Molari inferiori
Molares inferiores
Molaires inférieures

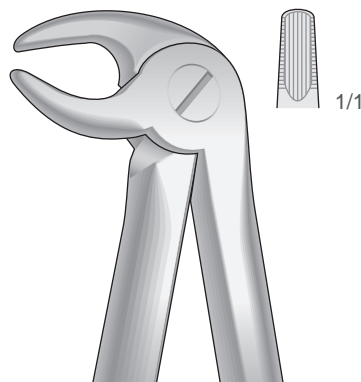


Fig. 13
50-260-13

Untere Prämolaren und Eckzähne
Lower premolars and cuspids
Canini e premolari inferiori
Caninos y premolares inferiores
Canines et prémolaires inférieures

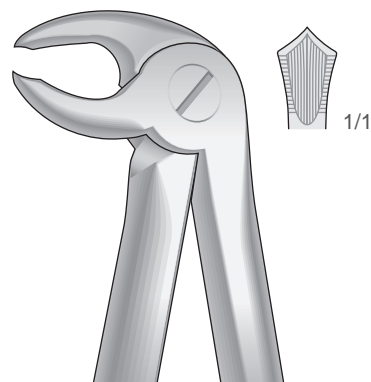

Fig. 22
50-260-22

Untere Molaren
Lower molars
Molari inferiori
Molares inferiores
Molaires inférieures

Zahnzangen, Paßformgriff
Extracting Forceps, Anatomical Handle
Pinze per estrazione, Manico anatomico
Pinzas da extracción, Mango anatómico
Daviers, Manche anatomique

Untere Weisheitszähne
Lower wisdom teeth
Denti del giudizio inferiori
Muelas del juicio inferiores
Dent de sagesse inférieures

Untere Prämolaren
Lower premolars
Premolari inferiori
Premolares inferiores
Prémolaires inférieures

Untere Molaren
Lower Molars
Molari inferiori
Molares inferiores
Molaires inférieures

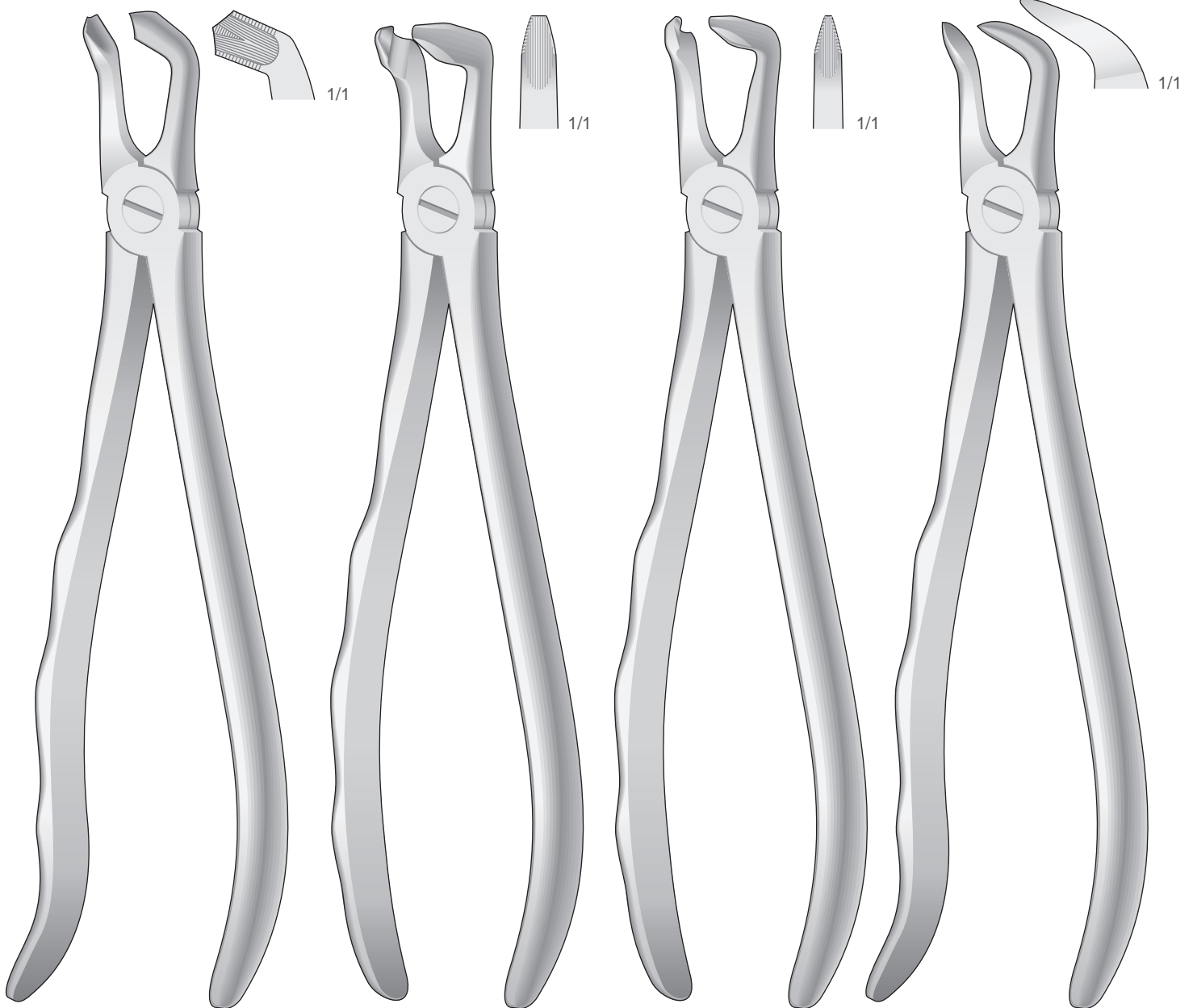


Fig. 79
50-270-79

Fig. 79N
50-280-79N

Fig. 46N
50-290-46N

Fig. 87
50-300-87

Zahnzangen, Paßformgriff
Extracting Forceps, Anatomical Handle
Pinze per estrazione, Manico anatomico
Pinzas da extracción, Mango anatómico
Daviers, Manche anatomique

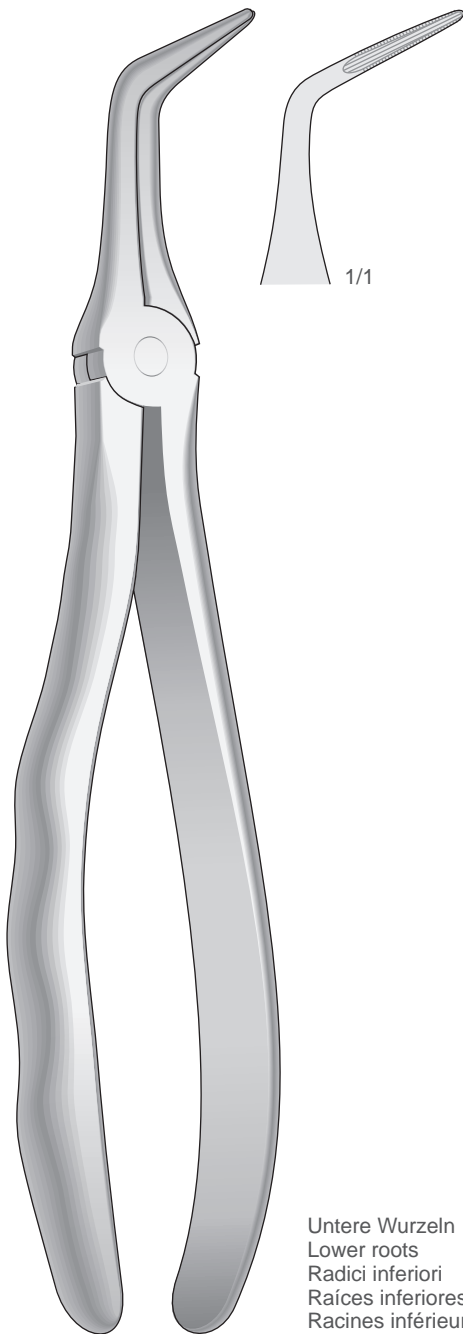


Fig. 46LX
50-310-46LX

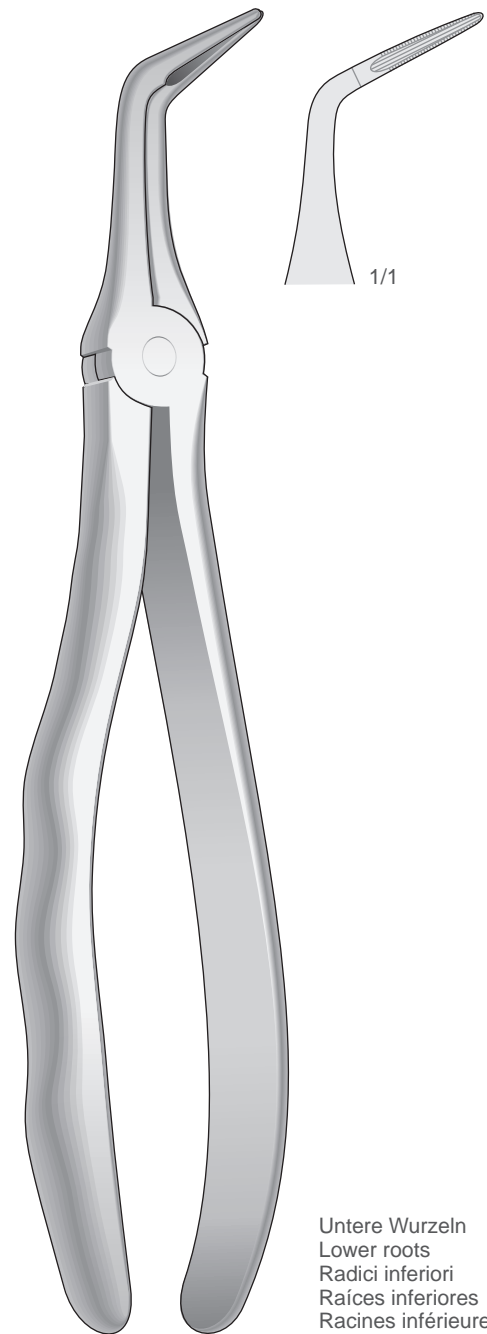
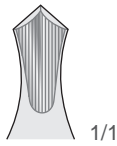
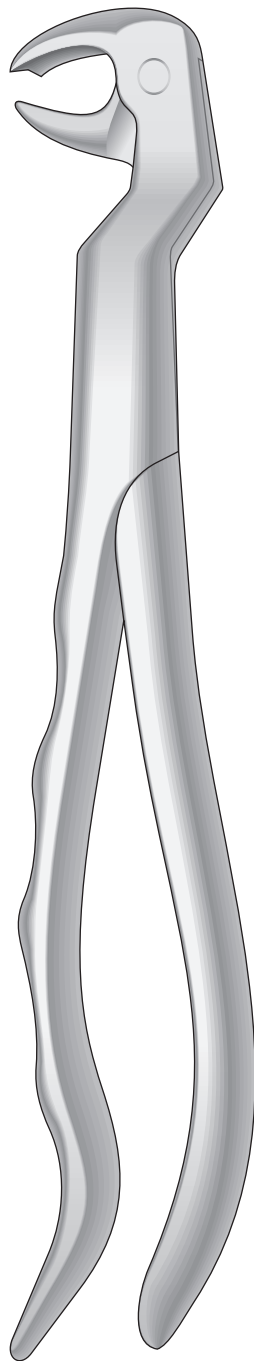


Fig. 46L
50-310-46L

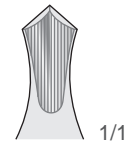
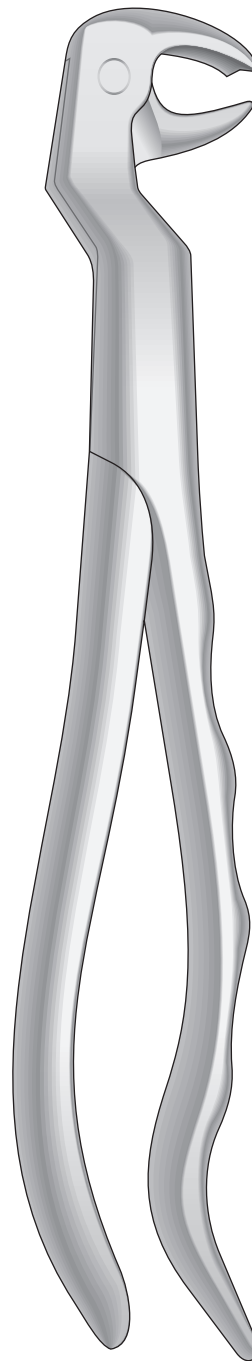
Zahnzangen, Paßformgriff
Extracting Forceps, Anatomical Handle
Pinze per estrazione, Manico anatomico
Pinzas da extracción, Mango anatómico
Daviers, Manche anatomique

Untere Molaren und Weisheitszähne
Lower molars and wisdom teeth
Molari e denti del giudizio inferiori
Molares y muelas del juicio inferiores
Molaires et dent de sagesse inférieures



Links
Left
Sinistra
Izquierdos
Gauches

50-320-22L

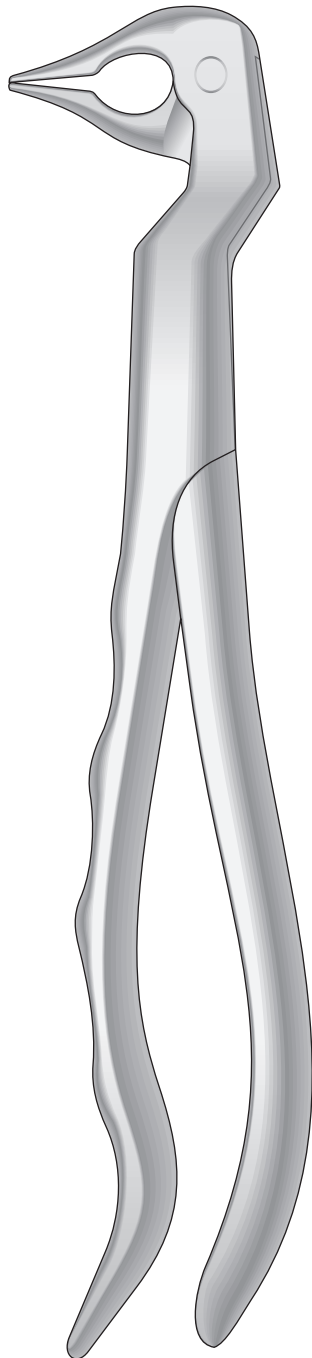


Rechts
Right
Destra
Derechos
Droites

50-320-22R

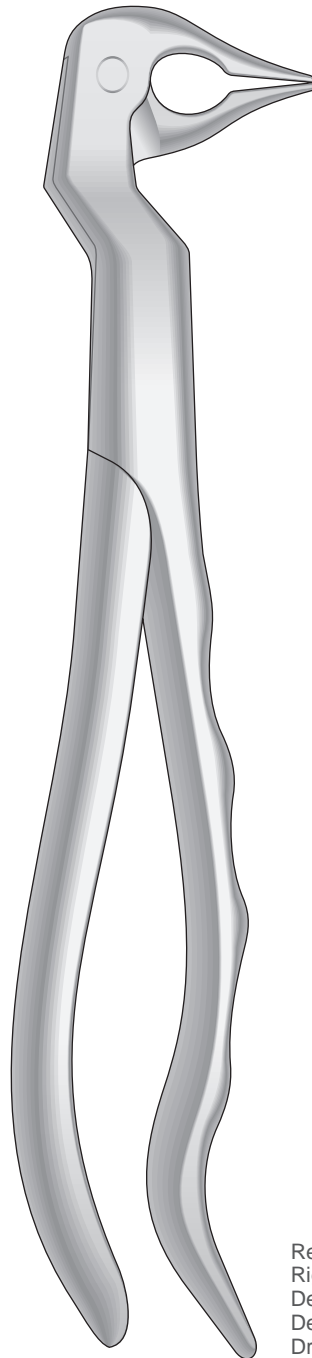
Zahnzangen, Paßformgriff
Extracting Forceps, Anatomical Handle
Pinze per estrazione, Manico anatomico
Pinzas da extracción, Mango anatómico
Daviers, Manche anatomique

Untere Wurzeln sehr feine
Lower very fine roots
Radici inferiori molto sottili
Raíces inferiores muy finas
Racines inférieures très fines



Links
Left
Sinistra
Izquierdos
Gauches

Fig.133
50-330-133L



Rechts
Right
Destra
Derechos
Droites

Fig.133
50-330-133R

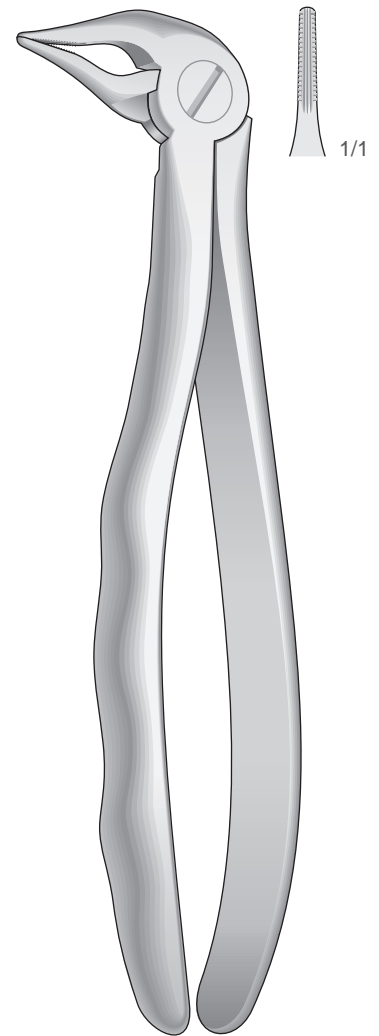


Fig.333S
50-340-333S

Zahnzangen, Amerikanische Form
Extracting Forceps, American Pattern
Pinze per estrazione, Forma Americana
Pinzas da extracción, Forma Americana
Daviers, Forme Américaine

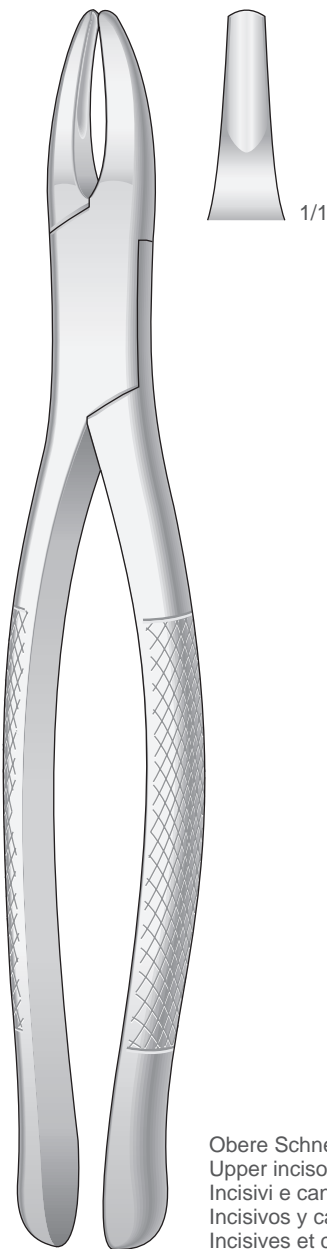
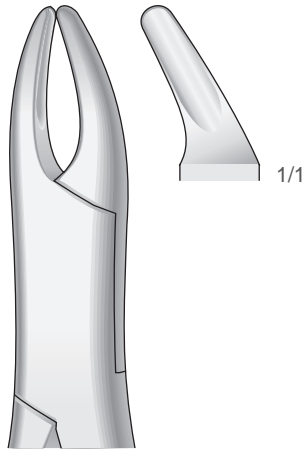


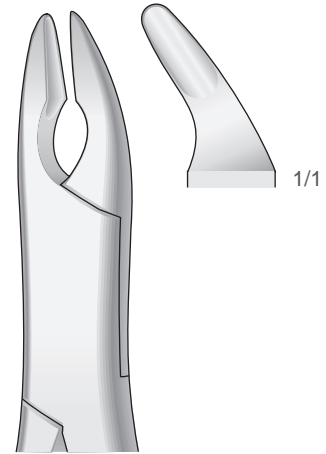
Fig. 1
50-350-1



CRYER

Fig. 150
50-350-150

Obere Prämolaren, Schneidezähne, Wurzeln
Upper Bicuspids, incisors and roots
Premolari, incisivi e radici superiori
Premolares, incisivos y raíces superiores
Prémolaires, incisives et racines supérieures



CRYER

Fig. 150A
50-350-150A

Obere Prämolaren, Schneidezähne, Wurzeln
Upper Bicuspids, incisors and roots
Premolari, incisivi e radici superiori
Premolares, incisivos y raíces superiores
Prémolaires, incisives et racines supérieures

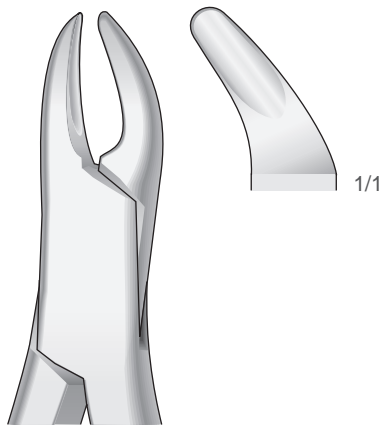


Fig. 62
50-350-62

Schneidezähne, Prämolaren, Milchzähne
Incisors, premolars, deciduous teeth
Incisivi, premolari, denti da latte Incisivos,
premolares, dientes de leche Incisives,
prémolaires, dents de lait

Obere Schneide- und Eckzähne
Upper incisors and cuspids
Incisivi e canini superiori
Incisivos y caninos superiores
Incisives et canines supérieures

Zahnzangen, Amerikanische Form
Extracting Forceps, American Pattern
Pinze per estrazione, Forma Americana
Pinzas da extracción, Forma Americana
Daviers, Forme Américaine

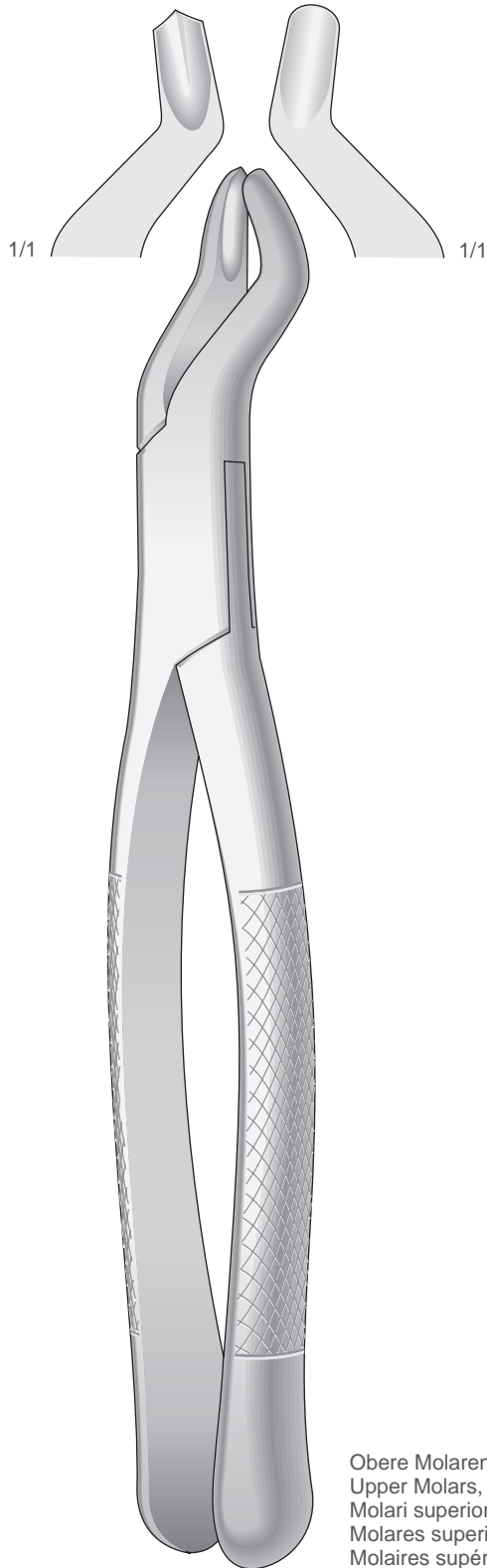


Fig. 53R
50-360-53R

Obere Molaren, Rechts
Upper Molars, Right
Molari superiori, Destra
Molares superiores, Derechos
Molaires supérieures, Droites

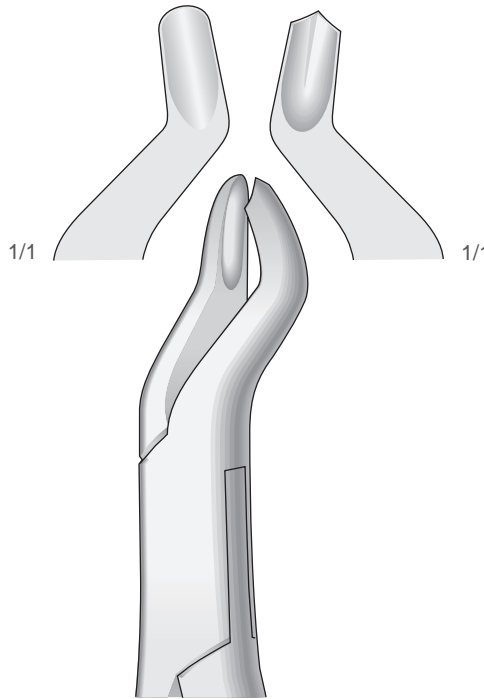
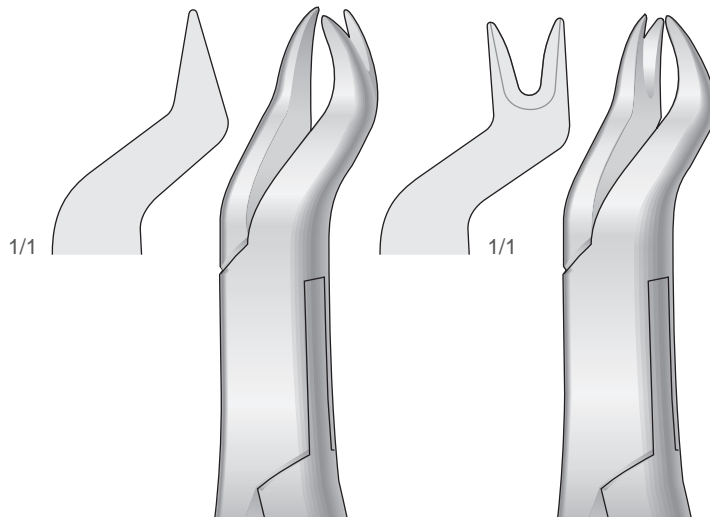


Fig. 53L
50-360-53L

Obere Molaren, Links
Upper Molars, Left
Molari superiori, Sinistra
Molares superiores, Izquierdos
Molaires supérieures, Gauches



NEVIUS

Fig. 88R
50-360-88R

Obere Molaren, Rechts
Upper Molars, Right
Molari superiori, Destra
Molares superiores, Derechos
Molaires supérieures, Droites

NEVIUS

Fig. 88L
50-360-88L

Obere Molaren, Links
Upper Molars, Left
Molari superiori, Sinistra
Molares superiores, Izquierdos
Molaires supérieures, Gauches

Zahnzangen, Amerikanische Form
Extracting Forceps, American Pattern
Pinze per estrazione, Forma Americana
Pinzas da extracción, Forma Americana
Daviers, Forme Américaine

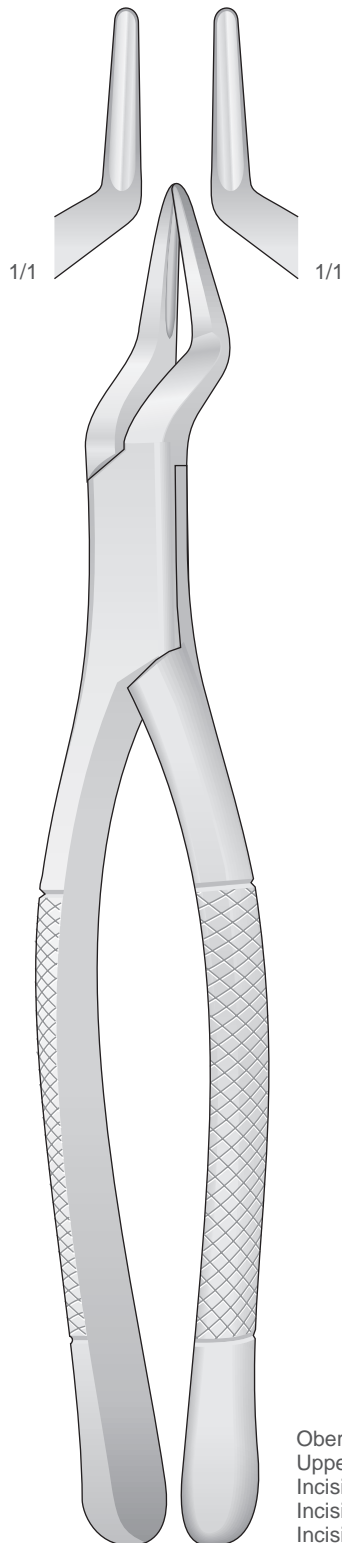
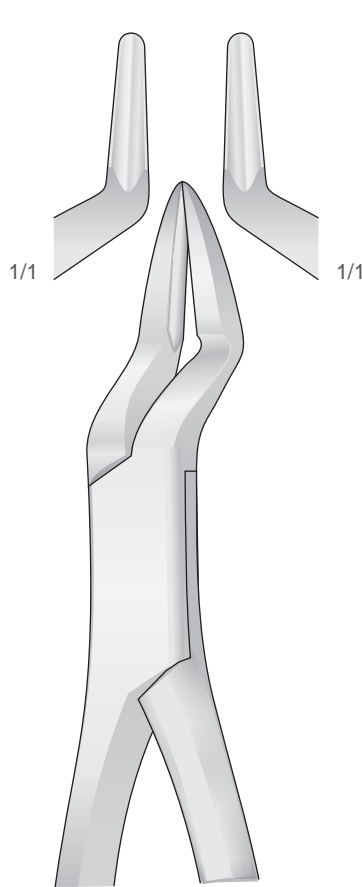


Fig.65
50-370-65

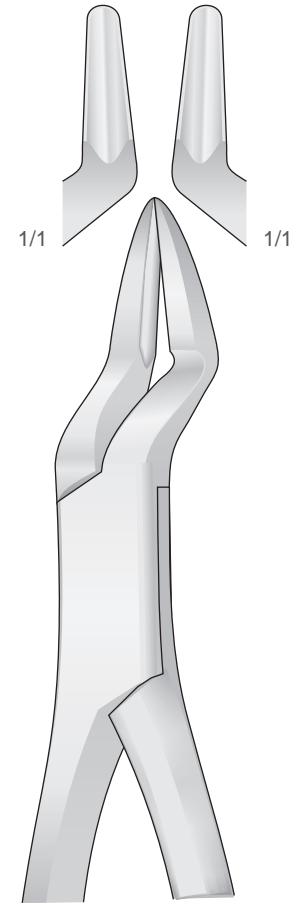
Obere Schneidezähne und Wurzeln
Upper Incisors and Roots
Incisivi e radici superiori
Incisivos y raíces superiores
Incisives et racines supérieures



PARMLY

Fig. 32A
50-370-32A

Obere Wurzeln und Prämolaren
Upper Roots and Premolars Radici
e premolari superiori Raices y
premolares superiores Racines et
prémolaires supérieures



PARMLY

Fig. 32
50-370-32

Obere Prämolaren und Molaren
Upper Premolars and Molars
Premolari e molari superiori
Premolares y Molares superiores
Prémolaires et Molaires supérieures

Zahnzangen, Amerikanische Form
Extracting Forceps, American Pattern
Pinze per estrazione, Forma Americana
Pinzas da extracción, Forma Americana
Daviers, Forme Américaine

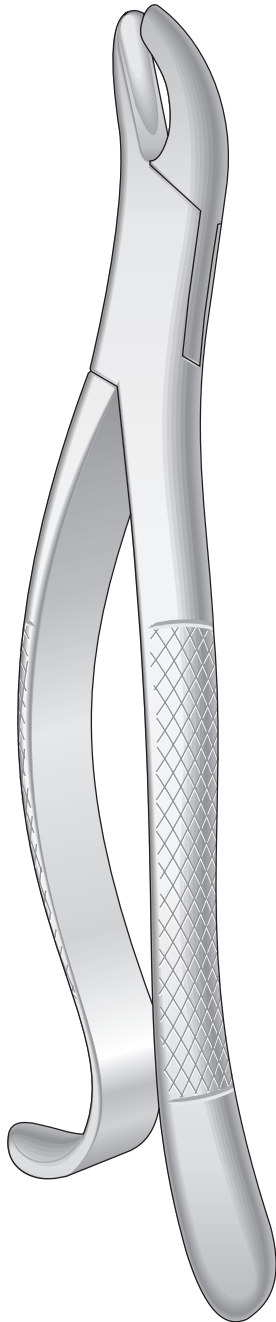
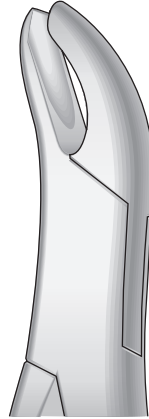


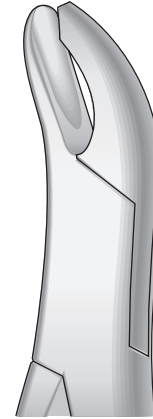
Fig. 24
50-380-24



HARRIS

Fig. 18R
50-380-18R

Obere Molaren, Rechts Upper
Molars, Right
Molari superiori, Destra
Molares superiores, Derechos
Molaires supérieures, Droites



HARRIS

Fig. 18L
50-380-18L

Obere Molaren, Links
Upper Molars, Left
Molari superiori, Sinistra
Molares superiores, Isquierdos
Molaires supérieures, Gauches

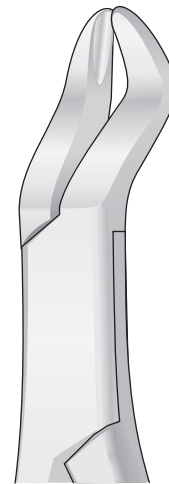
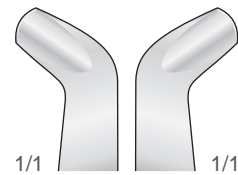
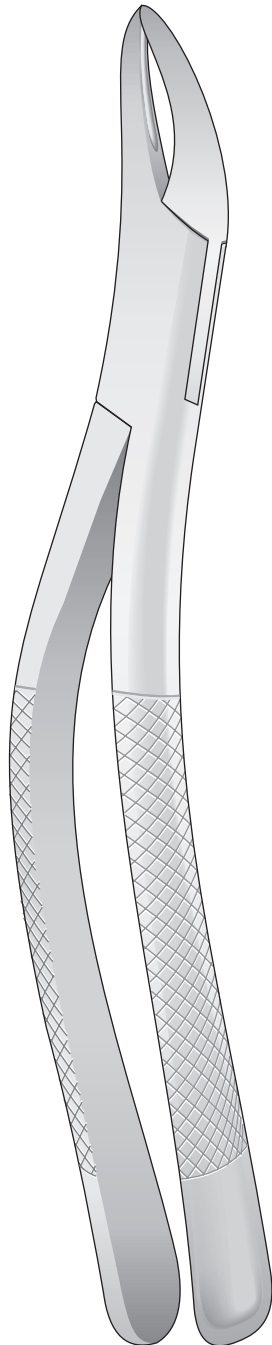
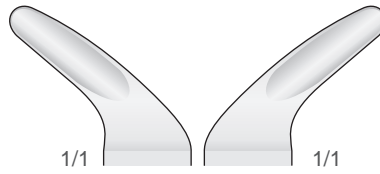
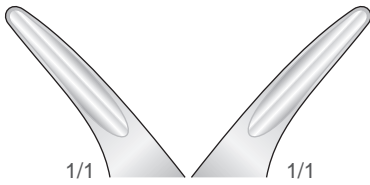


Fig. 210
50-380-210

Obere Molaren
Upper Molars Molari
superiori Molares
superiores Molaires
supérieures

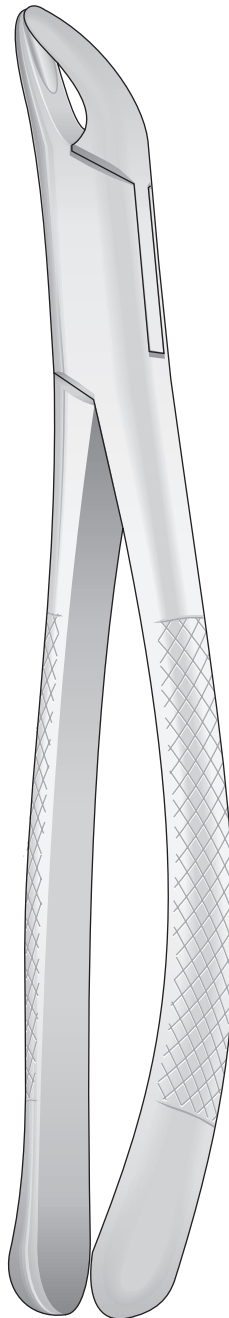
Zahnzangen, Amerikanische Form
Extracting Forceps, American Pattern
Pinze per estrazione, Forma Americana
Pinzas da extracción, Forma Americana
Daviers, Forme Américaine



Obere und Untere
Upper and lower
Superiori e inferiori
Superiores y inferiores
Supérieures et inférieures

Wurzeln
Roots
Radici
Raíces
Racines

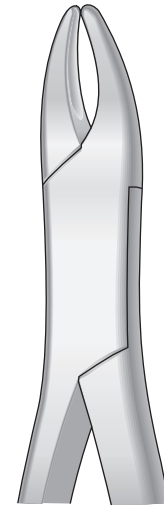
TOMES
Fig.69
50-390-69



Untere
Lower
Inferiori
Inferiores
Inférieures

Schneidezähne, Prämolaren, Wurzeln
Incisors, Premolars, Roots
Incisivi, premolari, radici
Incisivos, premolares, raíces
Incisives, prémolaires, racines

CRYER
Fig.151
50-400-151



HULL

Fig. 101
50-410-101

Für Eckzähne und Prämolaren,
Universalzange und Kinderzange
For canines and Premolars,
Universal and Tooth forceps for children
Canini e premolari,
universale e per bambini
Caninos y premolares,
universal y para niños
Canines et prémolaires,
universel et pour enfants

Zahnzangen, Amerikanische Form
Extracting Forceps, American Pattern
Pinze per estrazione, Forma Americana
Pinzas da extracción, Forma Americana
Daviers, Forme Américaine

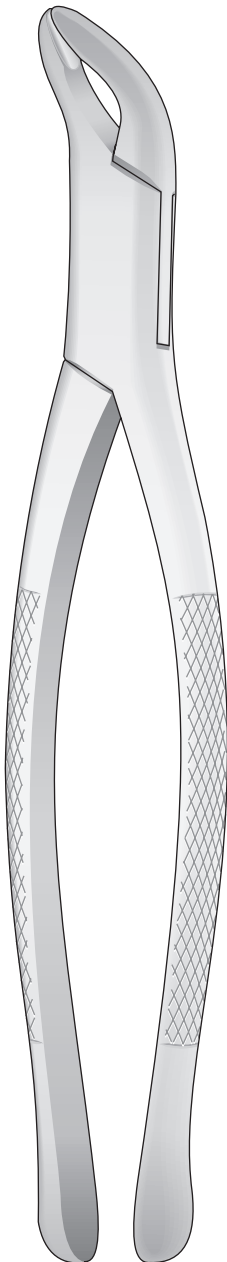
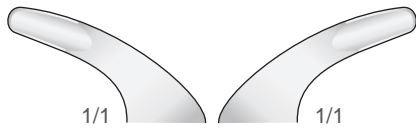


Fig. 203
50-420-203

Untere Schneidezähne, Prämolaren, Wurzeln
Lower Incisors, Premolars, Roots
Incisivi, premolari, radici inferiori
Incisivos, premolares, raices inferiores
Incisives, prémolaires, racines inférieures

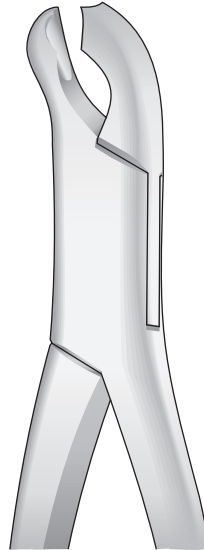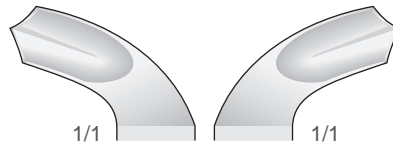


Fig. 17
50-420-17

Untere Molaren
Lower Molars
Molari inferiori
Molares inferiores
Molaires inférieures

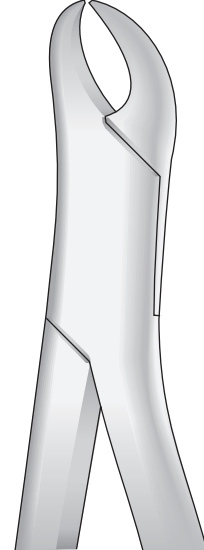
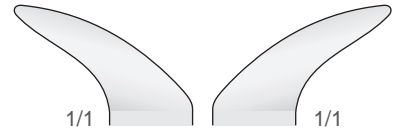


Fig. 23
50-420-23

Untere Molaren
Lower Molars
Molari inferiori
Molares inferiores
Molaires inférieures

Zahnzangen, Amerikanische Form
Extracting Forceps, American Pattern
Pinze per estrazione, Forma Americana
Pinzas da extracción, Forma Americana
Daviers, Forme Américaine

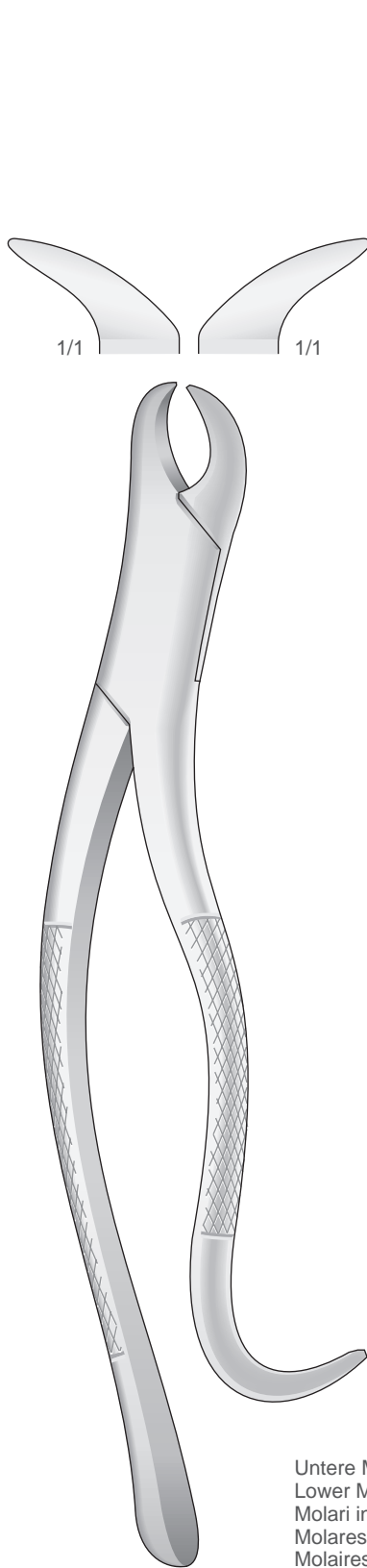
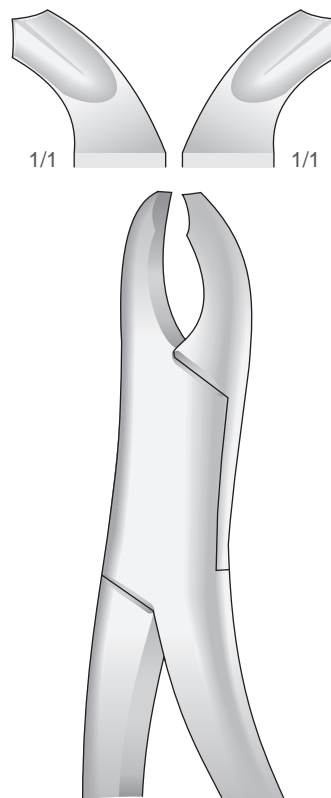


Fig. 16
50-430-16

Untere Molaren
Lower Molars
Molari inferiori
Molares inferiores
Molaires inférieures



HARRIS

Fig. 15
50-430-15

Untere Molaren
Lower Molars
Molari inferiori
Molares inferiores
Molaires inférieures

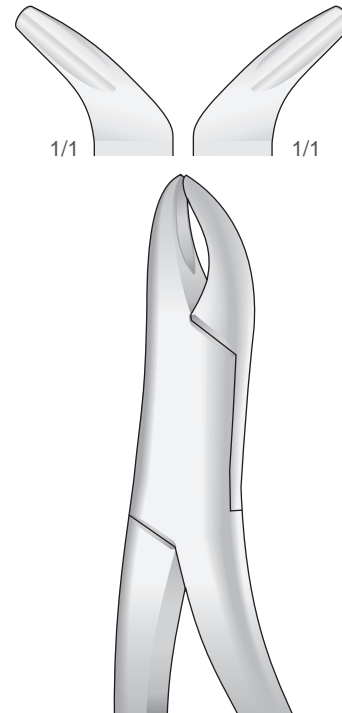


Fig. 103
50-430-103

Untere Schneidezähne, Prämolaren, Wurzeln
Lower Incisors, Premolars, Roots
Incisivi, premolari, radici inferiori
Incisivos, premolares, raíces inferiores
Incisives, prémolaires, racines inférieures

Zahnzangen, Amerikanische Form
Extracting Forceps, American Pattern
Pinze per estrazione, Forma Americana
Pinzas da extracción, Forma Americana
Daviers, Forme Américaine

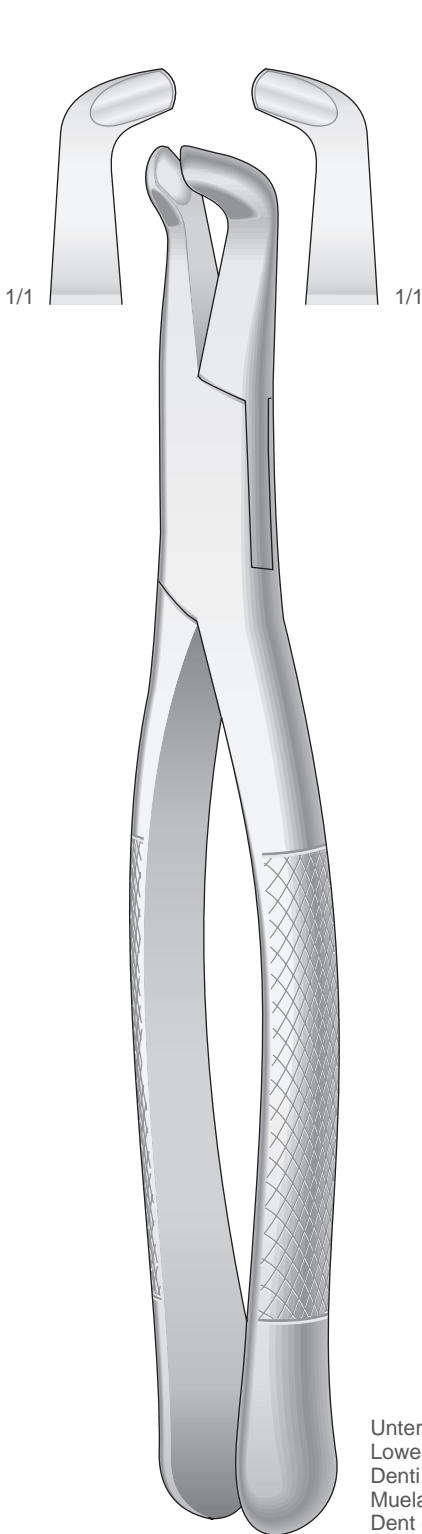
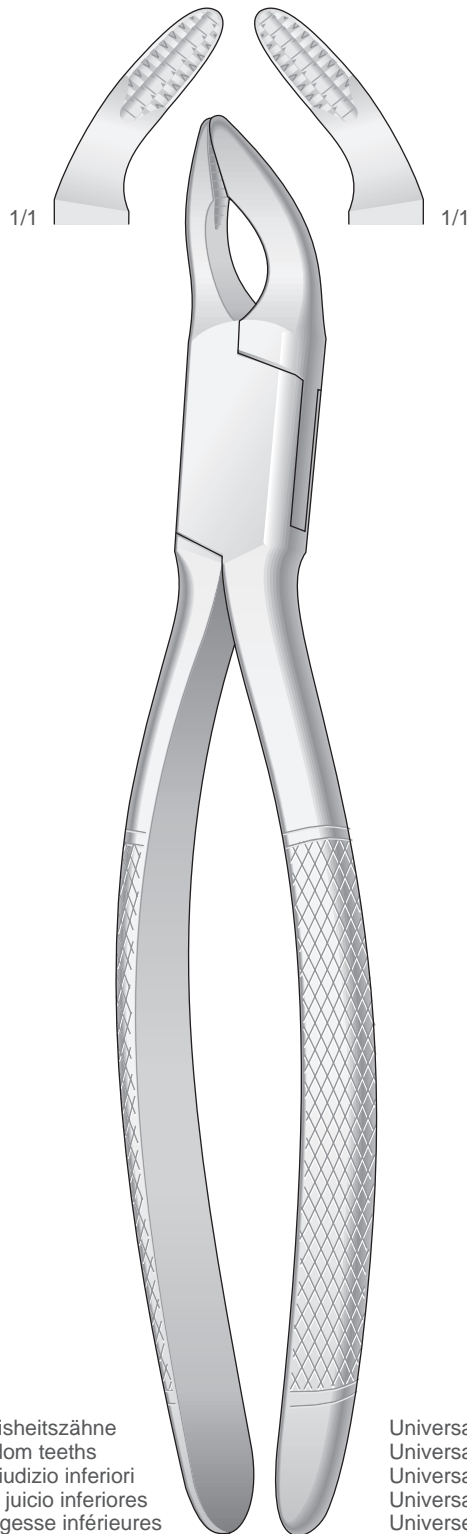
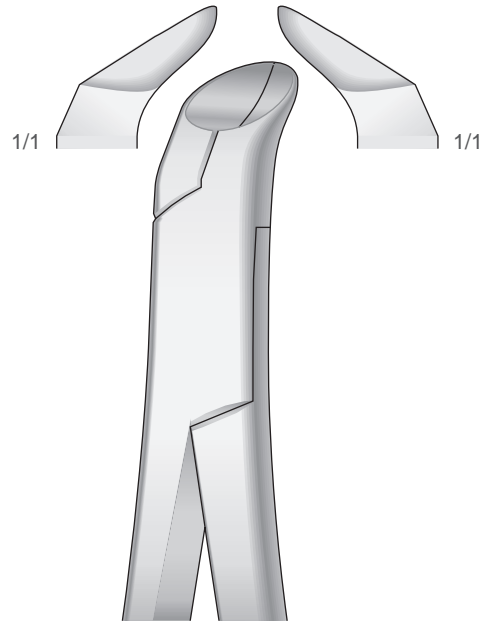


Fig. 222
50-440-222



COHEN
50-450-250



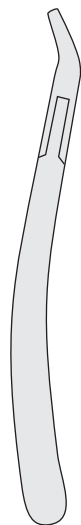
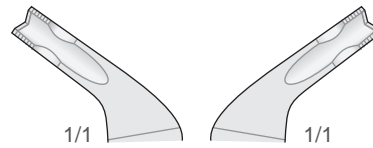
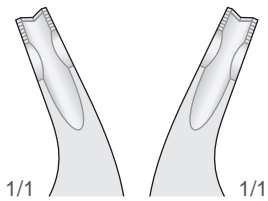
PHYSICK

Fig. 5
50-460-5

Untere Weisheitszähne
Lower wisdom teeth Denti
del giudizio inferiori Muelas
del juicio inferiores Dent de
sagesse inférieures

Universal
Universal
Universale
Universal
Universel

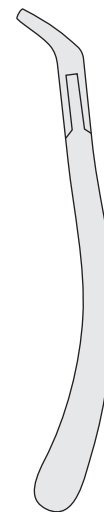Zahnzangen, Amerikanische Form
Extracting Forceps, American Pattern
Pinze per estrazione, Forma Americana
Pinzas da extracción, Forma Americana
Daviers, Forme Américaine



Obere
Upper
Superiori
Superiores
Supérieures

Prämolaren, Schneidezähne und Wurzeln
Bicuspid, incisors and roots
Premolari, incisivi e radici
Premolares, incisivos y raíces
Premolaires, incisives et racines

Fig. 150AS
50-470-150AS



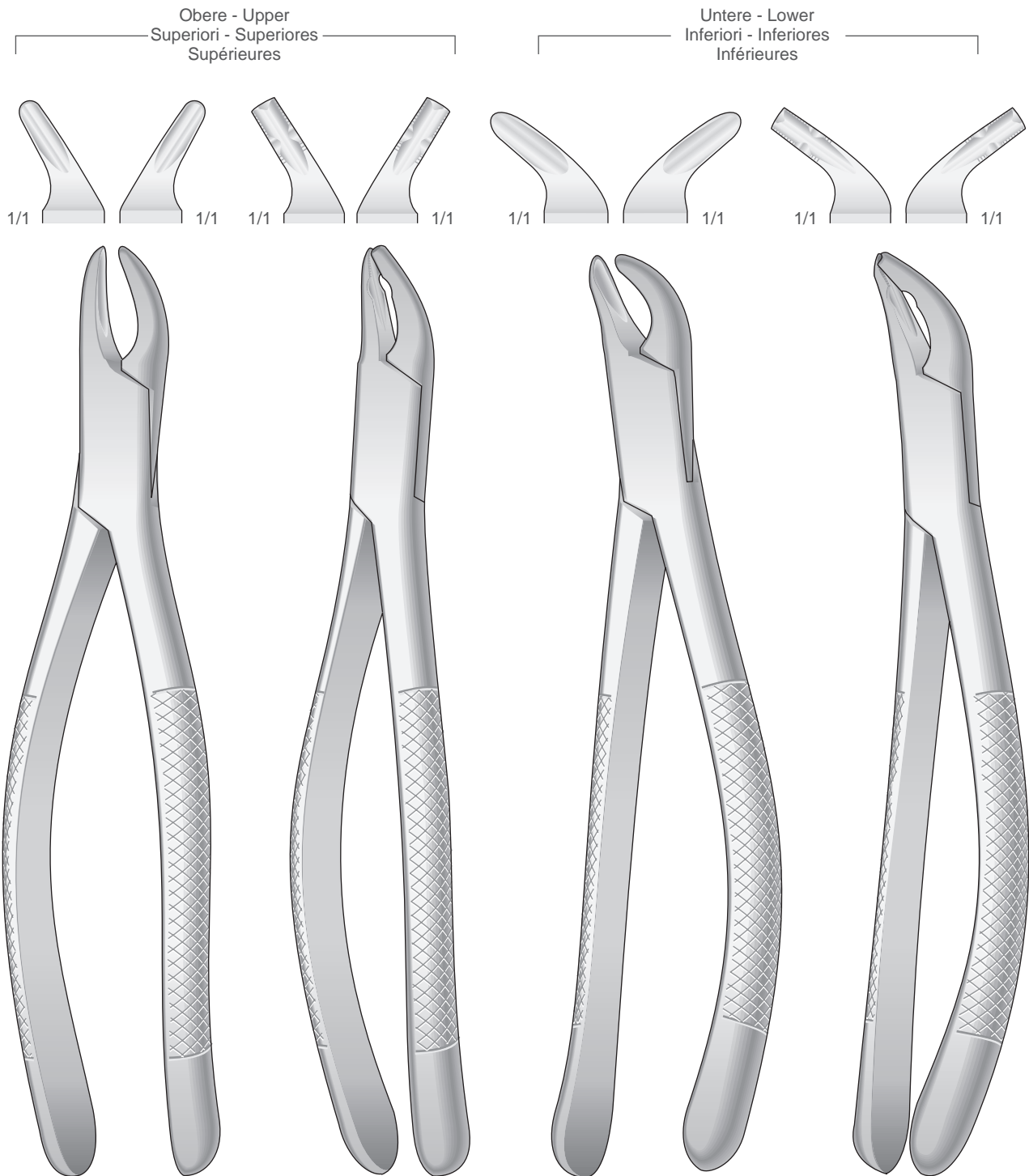
Untere
Lower
Inferiori
Inferiores
Inférieures

Prämolaren, Schneidezähne und Wurzeln
Bicuspid, incisors and roots
Premolari, incisivi e radici
Premolares, incisivos y raíces
Premolaires, incisives et racines

Fig. 151AS
50-480-151AS

Zahnzangen, Amerikanische Form
Extracting Forceps, American Pattern
Pinze per estrazione, Forma Americana
Pinzas da extracción, Forma Americana
Daviers, Forme Américaine

Für Kinder
For children
Per bambini
Para niños
Pour enfants



CRYER
Fig. 150 S
50-490-150S

Fig. 150 XAS
50-500-150XAS

CRYER
Fig. 151 S
50-490-151S

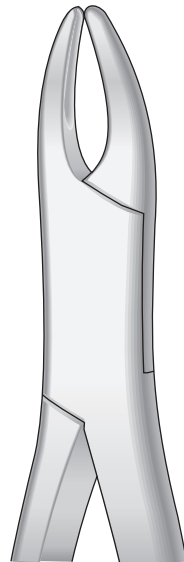
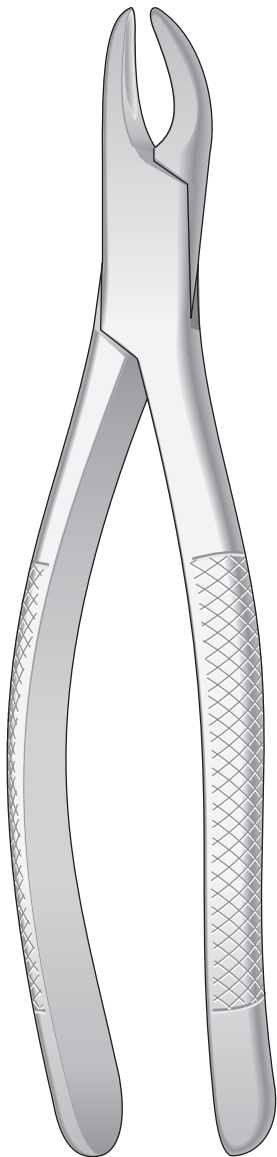
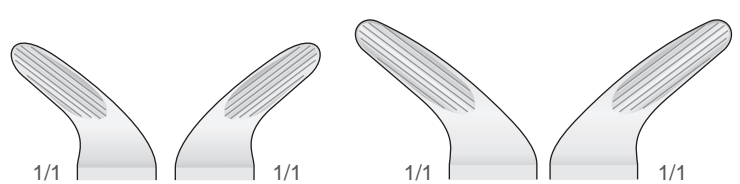
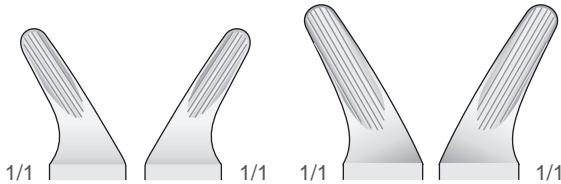
Fig. 151 XAS
50-500-151XAS

Zahnzangen, Amerikanische Form
Extracting Forceps, American Pattern
Pinze per estrazione, Forma Americana
Pinzas da extracción, Forma Americana
Daviers, Forme Américaine

Geriefte - Serrated - Striata - Estriadas - Striées

Obere Schneidezähne, Prämolaren, Wurzeln
Upper incisors, premolars, roots
Incisivi, premolari e radici superiori
Incisivos, premolares y raíces superiores
Incisives, premolaires et racines supérieures

Untere Schneidezähne, Prämolaren, Wurzeln
Lower incisors, premolars, roots
Incisivi, premolari e radici inferiori
Incisivos, premolares y raíces inferiores
Incisives, premolaires et racines inférieures



CRYER

Fig. 150
50-510-150

Für Erwachsene
For adults
Per adulti
Para adultos
Pour adults

Für Kinder
For children
Per bambini
Para niños
Pour enfants



CRYER

Fig. 151
50-520-151

Für Erwachsene
For adults
Per adulti
Para adultos
Pour adults

Für Kinder
For children
Per bambini
Para niños
Pour enfants

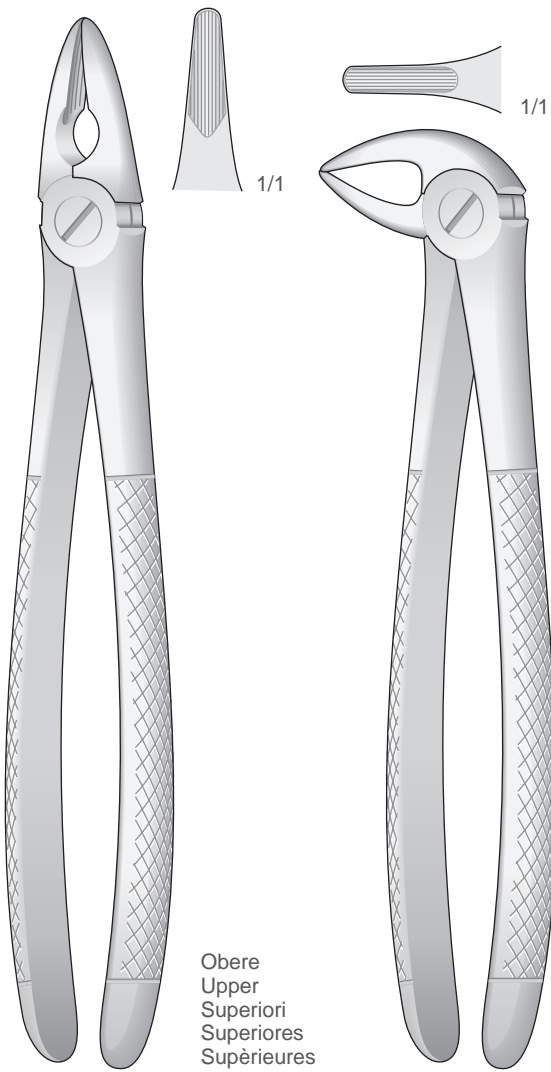
CRYER
Fig.150 S
50-510-150S

CRYER
Fig.151 S
50-520-151S

Zahnzangen
Extracting Forceps
Pinze per estrazione
Pinzas da extracción
Daviers

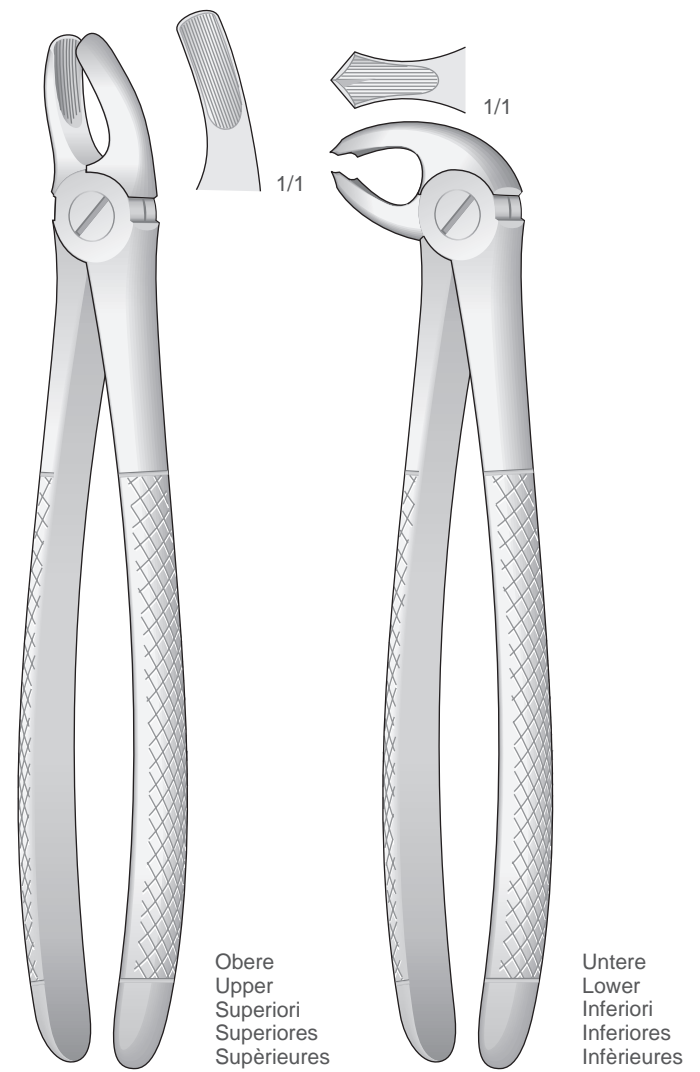
Schneidezähne, Eckzähne, Wurzeln
Incisors, bicuspid and roots
Incisivi, canini e radici
Incisivos, caninos y raíces
Incisives, canines et racines

Molaren
Molars
Molari
Molares
Molaires



Obere
Upper
Superiori
Superiores
Supérieures

Untere
Lower
Inferiori
Inferiores
Inférieures



Obere
Upper
Superiori
Superiores
Supérieures

Untere
Lower
Inferiori
Inferiores
Inférieures

MEAD
50-530-1

MEAD
50-530-3

MEAD
50-530-2

MEAD
50-530-4

Kinderzahnzangen, Amerikanische Form
Extracting Forceps for children, American Pattern
Pinze per estrazione per bambini, Forma Americana
Forceps dentales para niños, Forma Americana
Daviers pour enfants, Forme Américaine

Molaren
Pedo Lower Molars
Molari
Molares
Molaires

Molaren
Pedo Lower Molars
Molari
Molares
Molaires

Zähne und wurzeln
Pedo upper incisors
Bicuspids and roots
Denti e radici
Dientes y raíces
Dentes et racines

Zähne und wurzeln
Pedo lower incisors
Bicuspids and roots
Denti e radici
Dientes y raíces
Dentes et racines

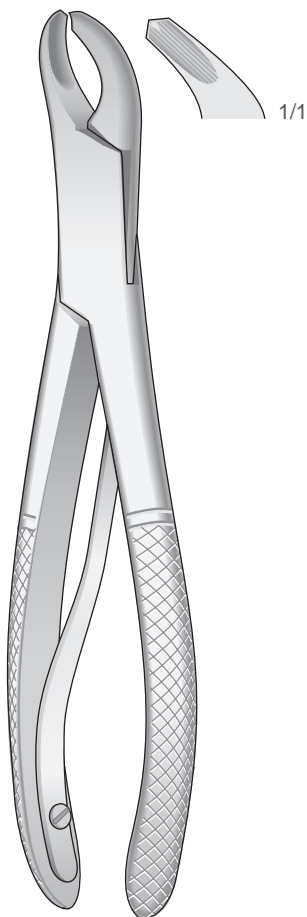


Fig. 17SK
50-540-17SK

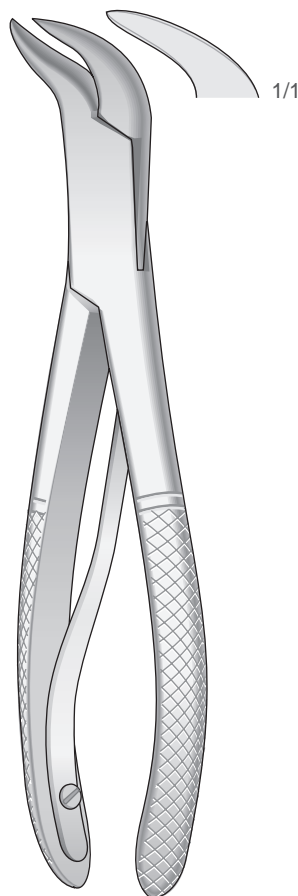


Fig. 23SK
50-550-23SK

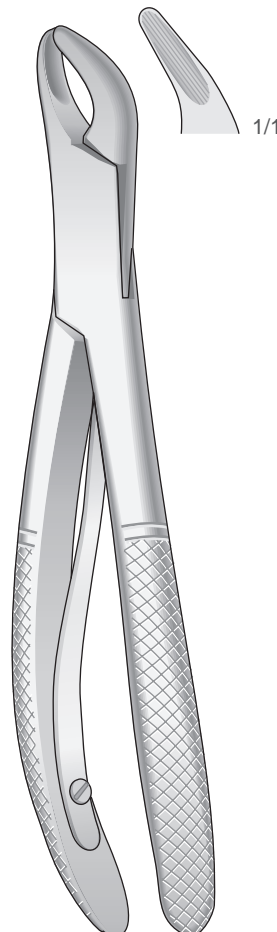


Fig. 150SK
50-560-150SK

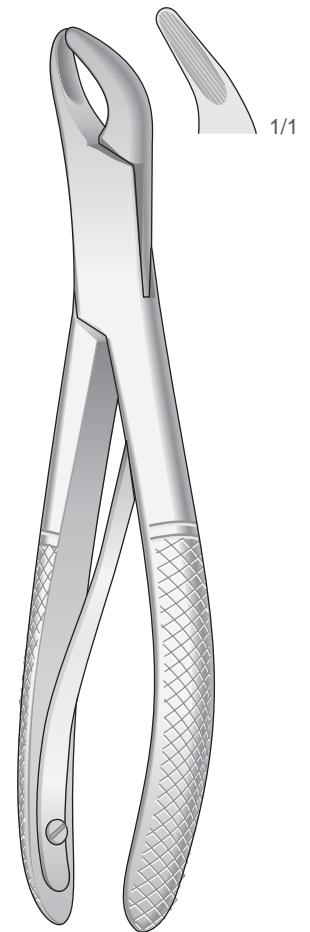


Fig. 151SK
50-570-151SK

Kinderzahnzangen
Extracting Forceps for children
Pinze per estrazione per bambini
Forceps dentales para niños
Daviers pour enfants

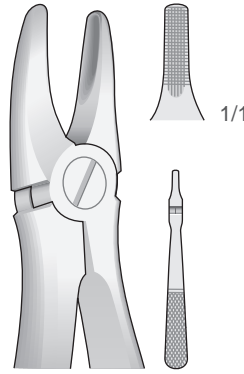


Fig. 137
50-580-137

Obere Schneidezähne
Upper Incisors Incisivi
superiori Incisivos
superiores Incisives
supérieures

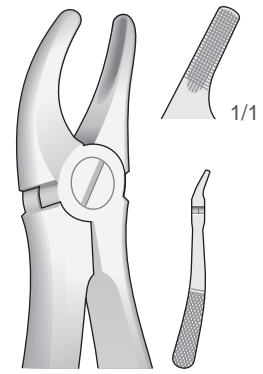


Fig. 139
50-580-139

Obere Prämolaren
Upper Premolars
Premolari superiori
Premolares superiores
Prémolaires supérieures

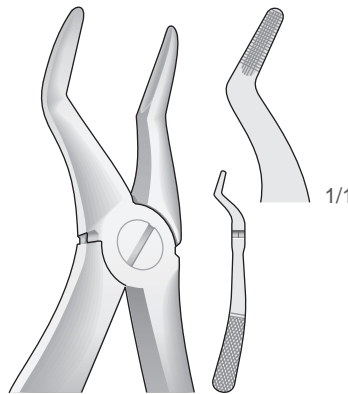


Fig. 51S
50-580-51S

Obere Wurzeln
Upper roots
Radici superiori
Raíces superiores
Racines supérieures

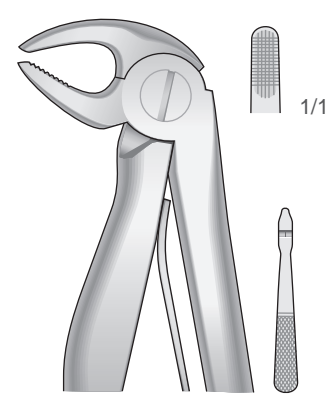
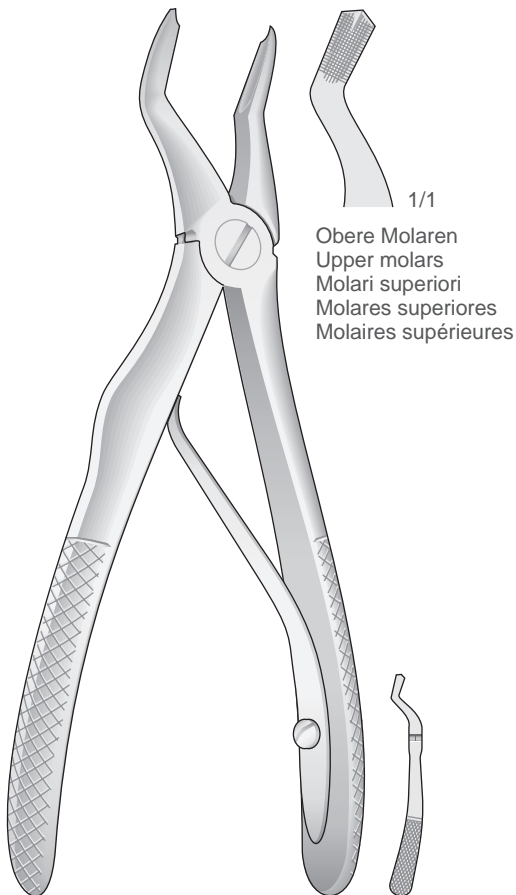


Fig. 5
50-580-5

Untere Schneidezähne
Lower incisors Incisivi
inferiori Incisivos
inferiores Incisives
inférieures



50-580-3

Obere Molaren
Upper molars
Molari superiori
Molares superiores
Molaires supérieures

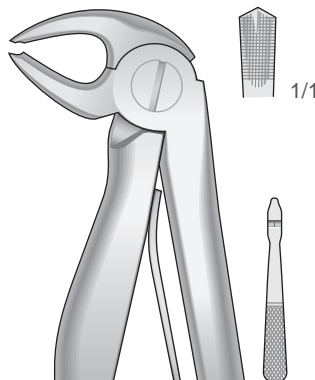


Fig. 6
50-580-6

Untere Molaren
Lower Molars
Molari inferiori
Molares inferiores
Molaires inférieures

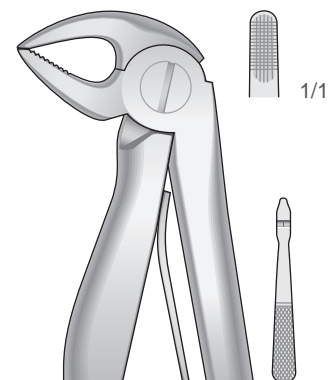
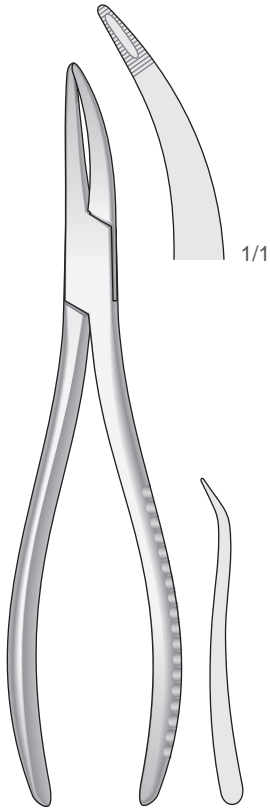


Fig. 7
50-580-7

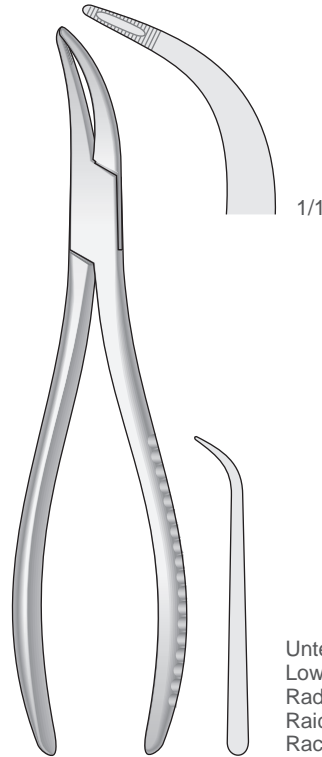
Untere Wurzeln
Lower roots
Radici inferiori
Raíces inferiores
Racines inférieures

Zahnzangen
Extracting Forceps
Pinze per estrazione
Pinzas da extracción
Daviers



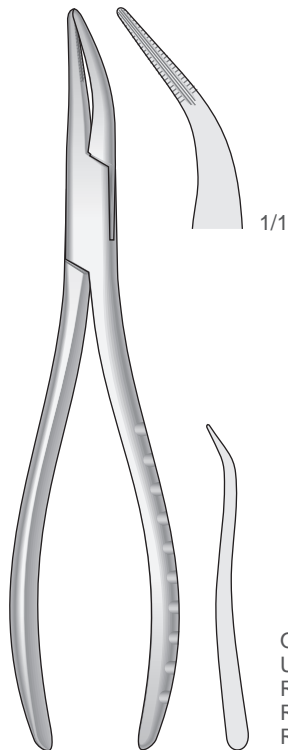
Obere Wurzeln, Universal
Upper roots, Universal
Radici superiori, Universale
Raices superiores, Universal
Racines superieures, Universel

WITZEL
170 mm
50-590-17



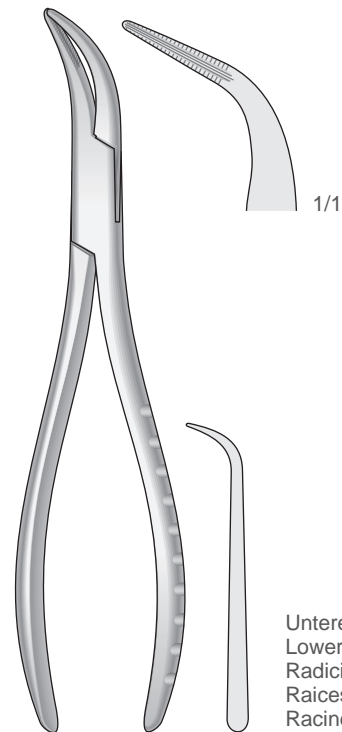
Untere Wurzeln, Universal
Lower roots, Universal
Radici inferiori, Universale
Raices inferiores, Universal
Racines inferieures, Universel

WITZEL
165 mm
50-590-16



Obere Wurzeln, Universal
Upper roots, Universal
Radici superiori, Universale
Raices superiores, Universal
Racines superieures, Universel

165 mm
50-600-01



Untere Wurzeln, Universal
Lower roots, Universal
Radici inferiori, Universale
Raices inferiores, Universal
Racines inferieures, Universel

160 mm
50-600-02

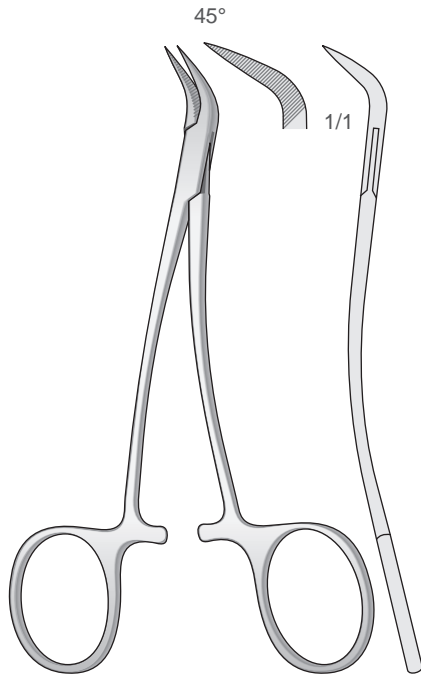
Wurzelfragmentinstrumente

Root Fragment Forceps

Strumenti per frammenti di radici

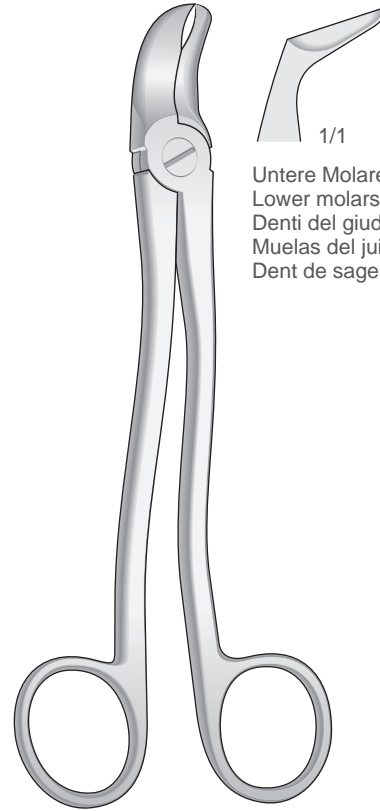
Instrumentos para fragmentos de raíces

Instrumentos pour fragments de racines



PEET

120 mm
50-610-12

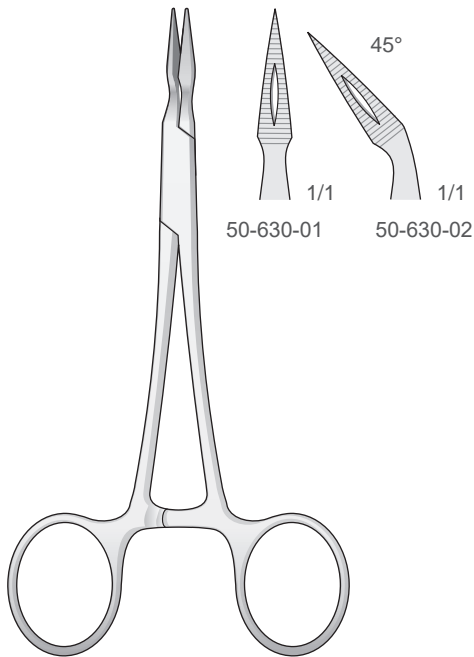


1/1

Untere Molaren und Weisheitszähne
Lower molars and wisdom teeth
Denti del giudizio e molari inferiori
Muelas del juicio y molares inferiores
Dent de sagesse et molaires inférieures

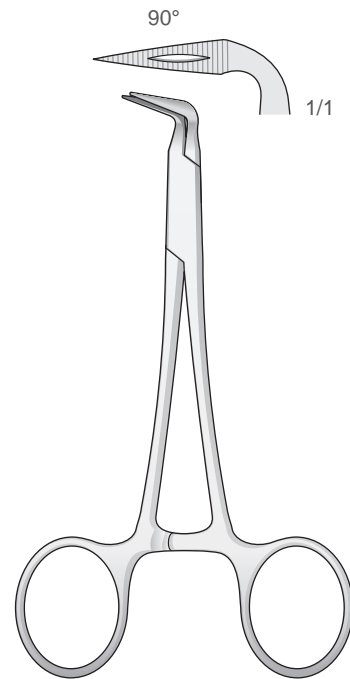
175 mm
50-620-17

Wurzelfragmente
Root fragments
Frammenti di radici
Fragmentos de raíces
Fragments de racines



STIEGLITZ

140 mm
50-630-14



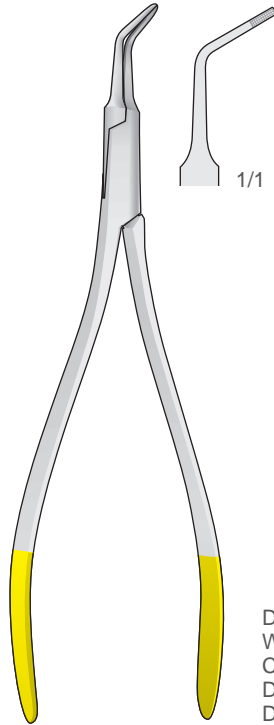
90°

1/1

STIEGLITZ

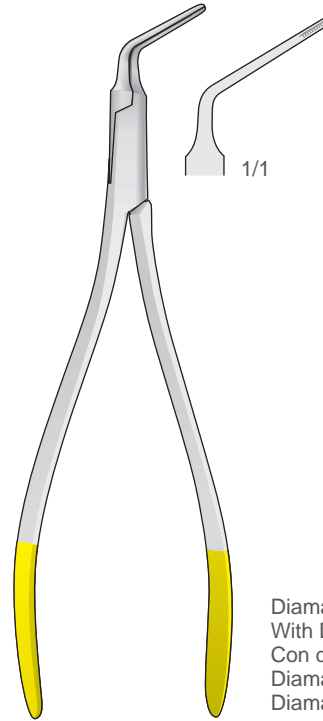
120 mm
50-640-12

Wurzelfragmentinstrumente
Root Fragment Forceps
Strumenti per frammenti di radici
Instrumentos para fragmentos de raíces
Instruments pour fragments de racines



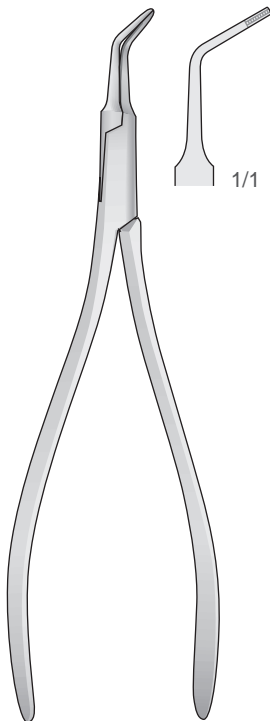
Diamantiert
With Diamond
Con diamante
Diamantada
Diamantées

130 mm
50-650-01

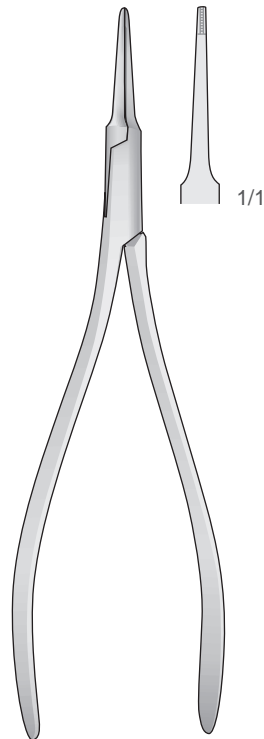


Diamantiert
With Diamond
Con diamante
Diamantada
Diamantées

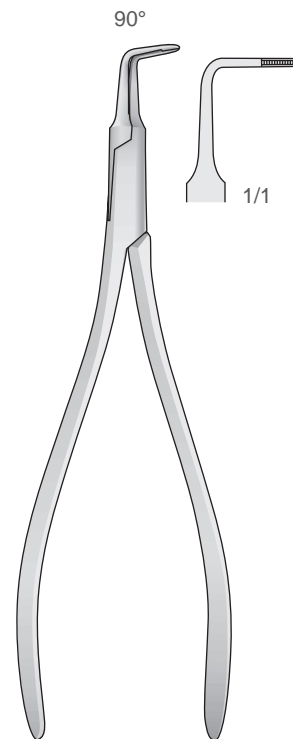
130 mm
50-650-02



130 mm
50-660-01



130 mm
50-660-02



125 mm
50-660-03